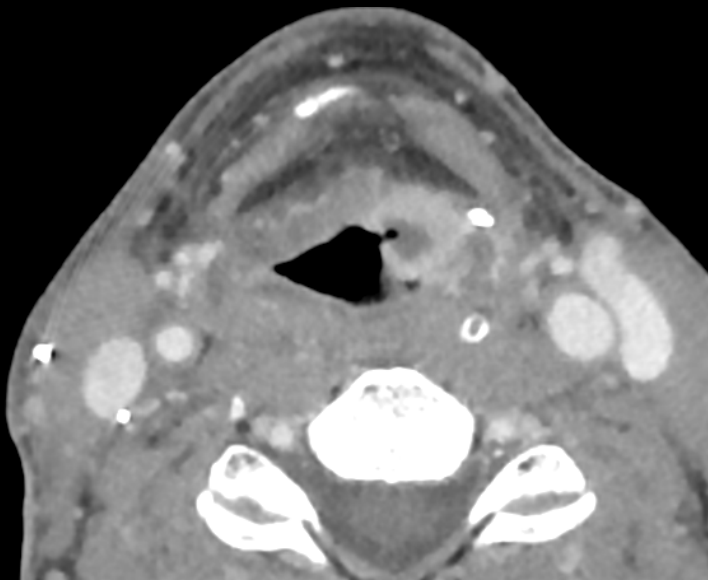
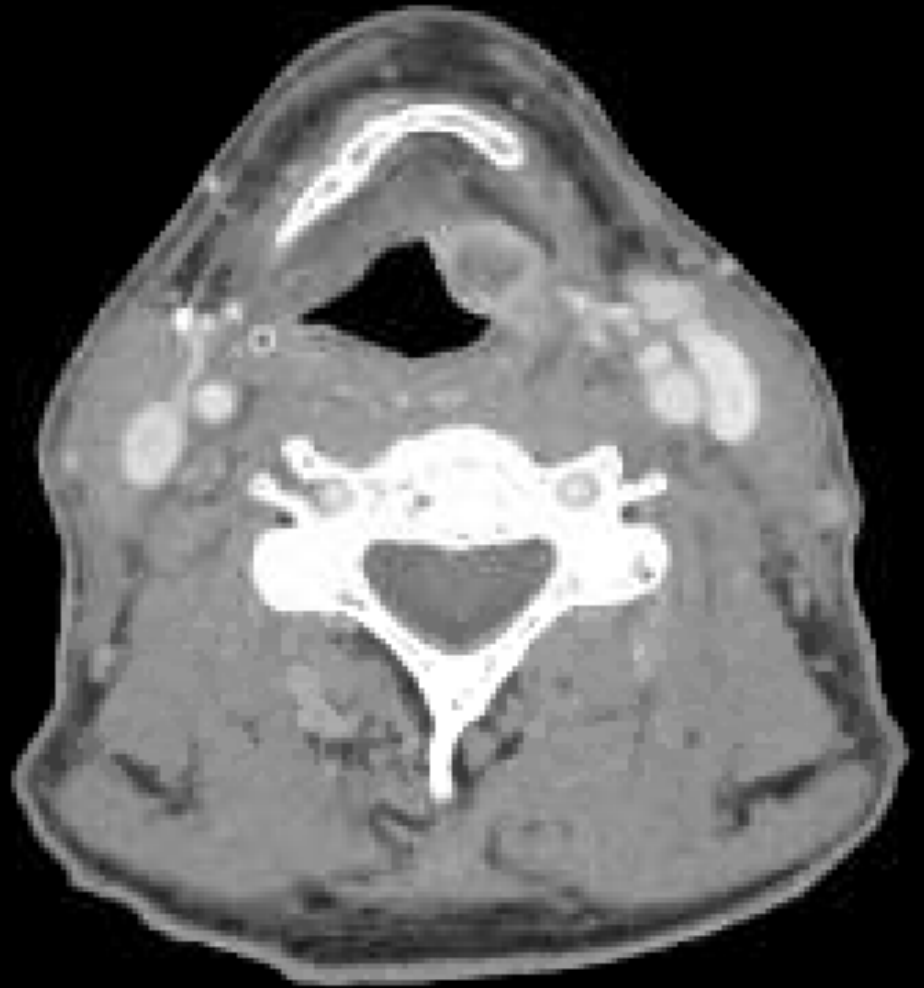
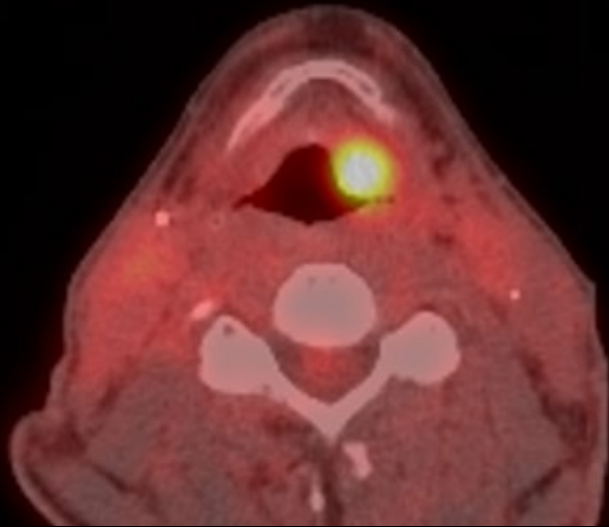


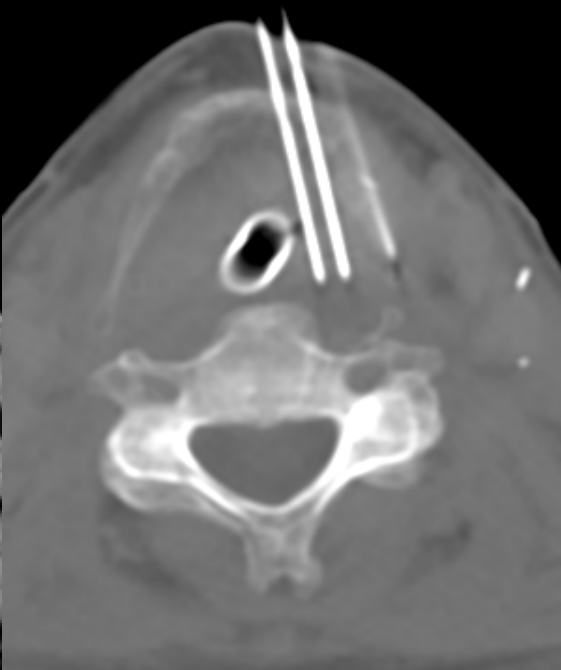
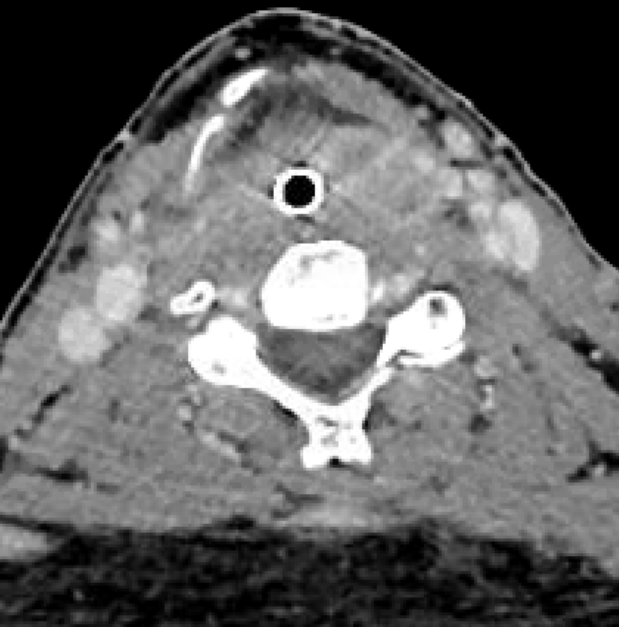
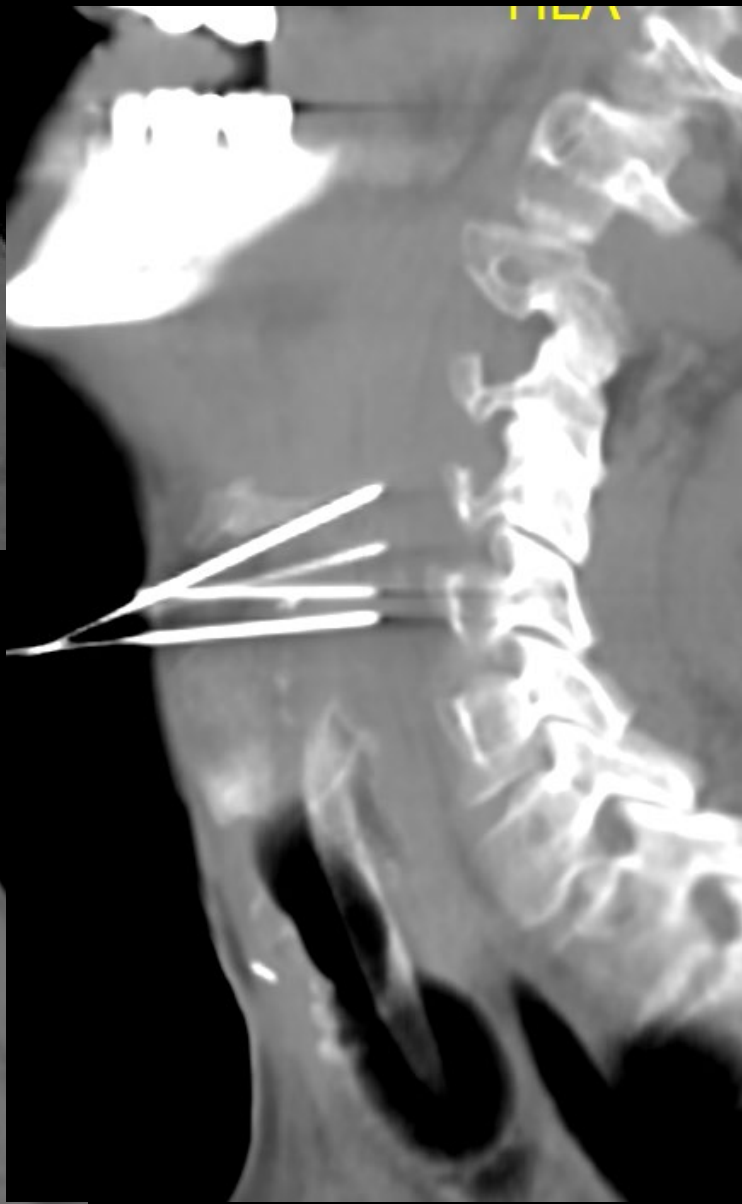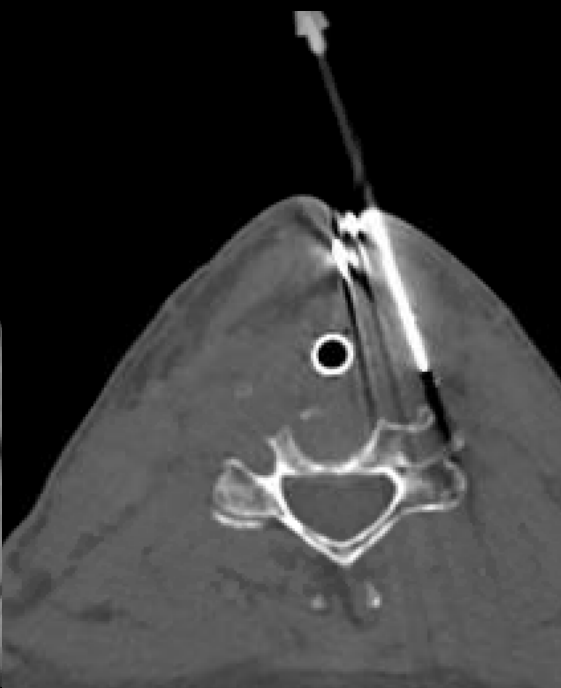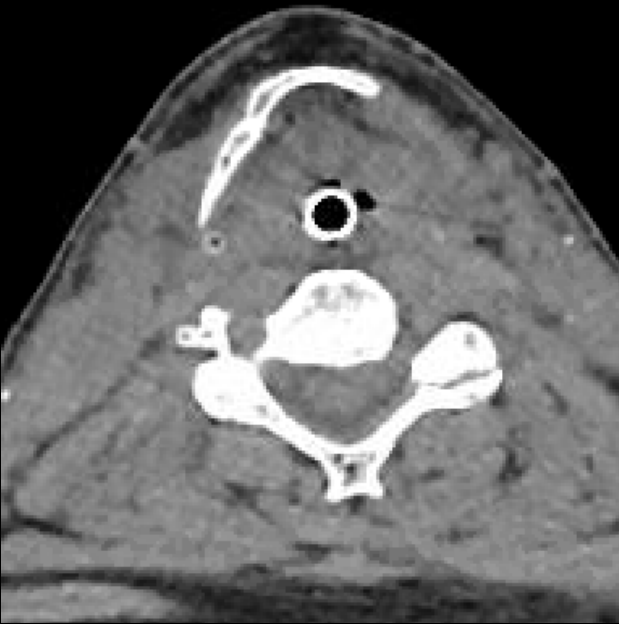
L'auriez vous fait?

75 ans

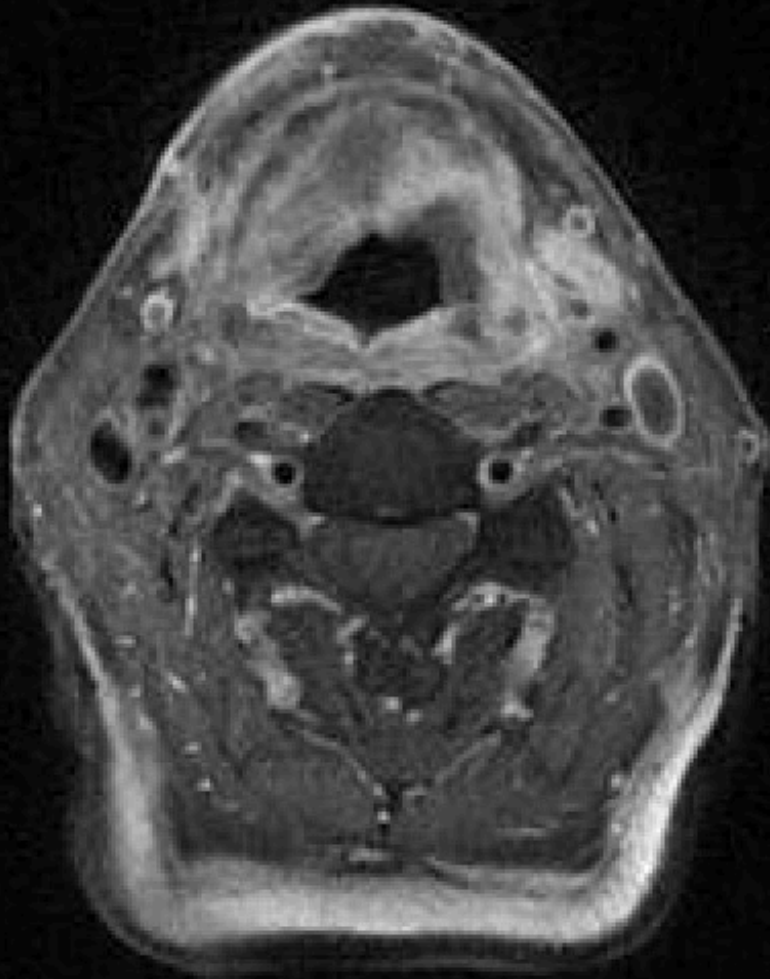
- Carcinoïde atypique de l'épiglotte
 - 2019 : laryngectomie supra glottique + curage
 - 4 mitoses, 15% de KI 67, N+
 - Radiothérapie en 21
 - Somatuline
 - Folfox
 - Deticene



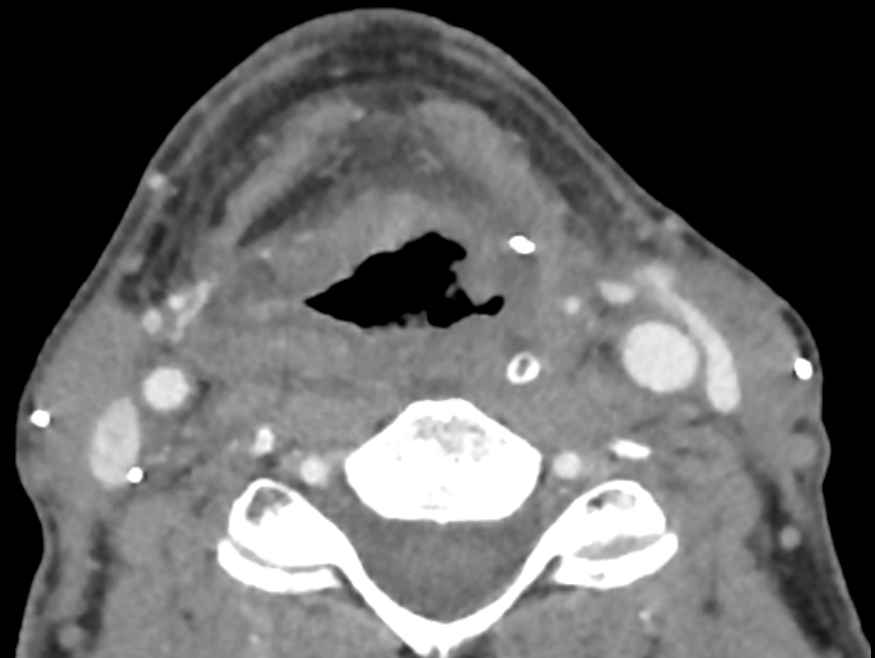
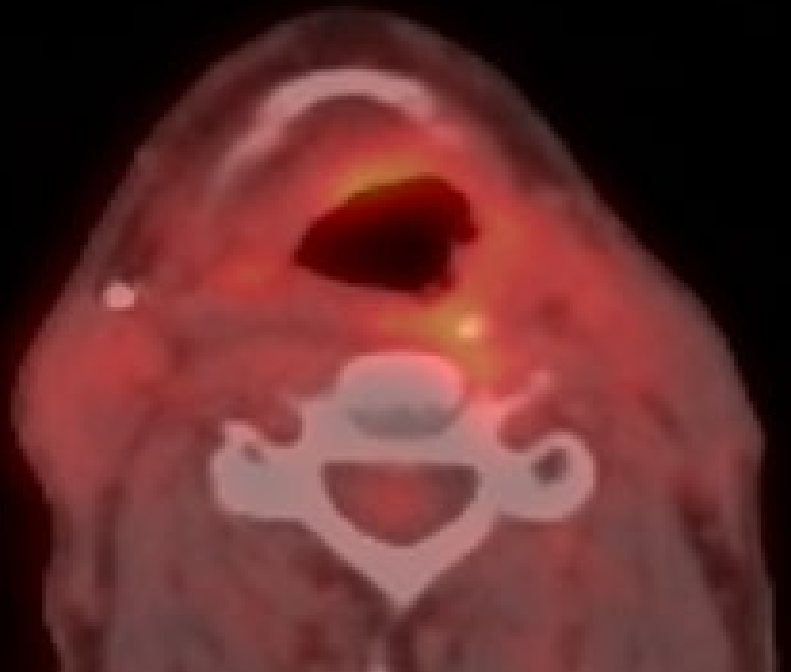
Quelle technique ?

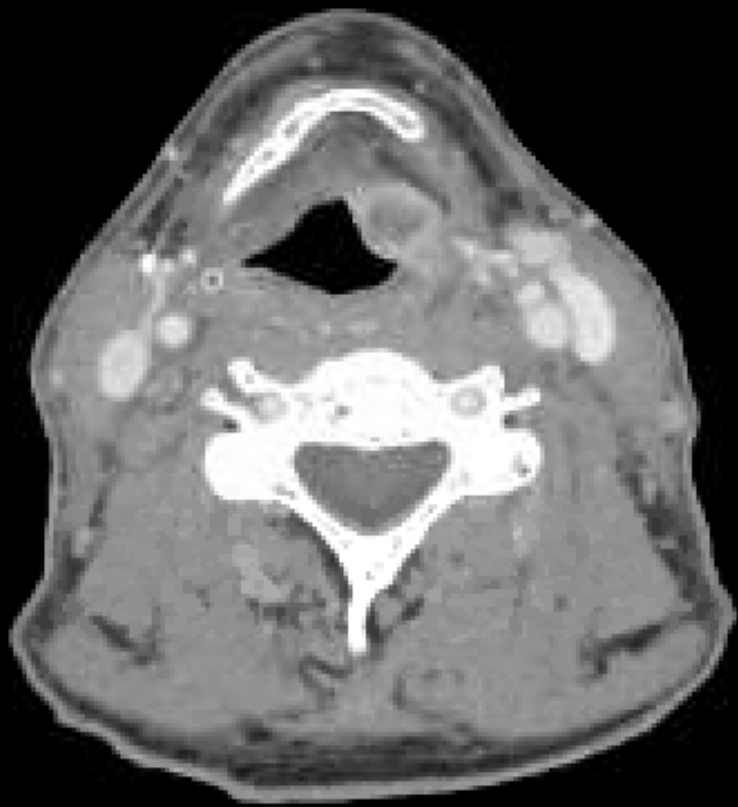


H

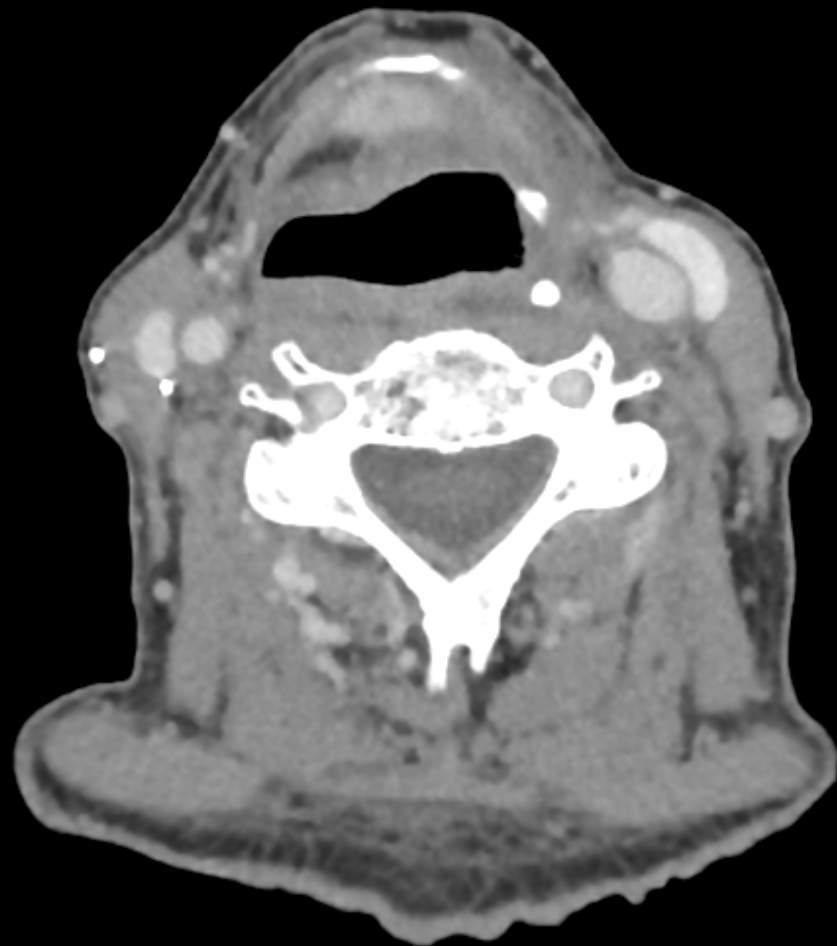


3 months





Pre-Ttt



12 mois