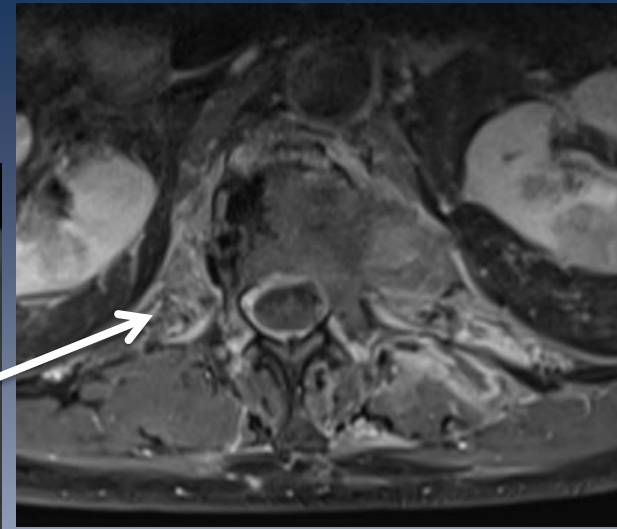
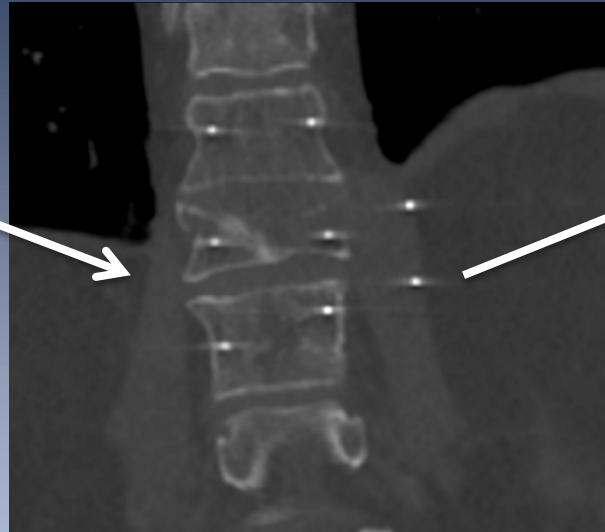
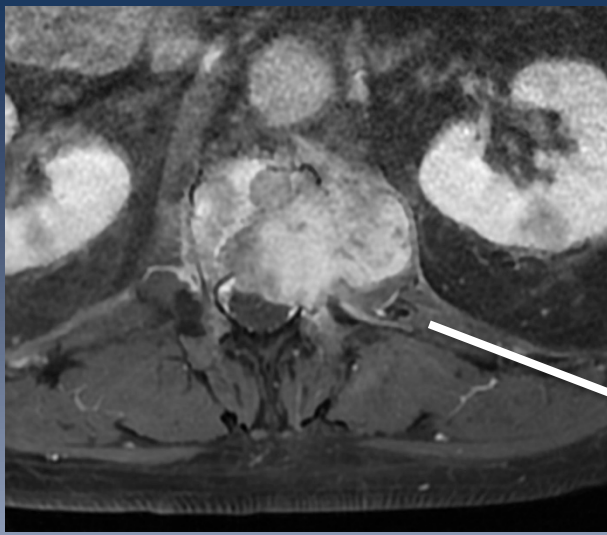
Electro-chimiotherapie des épidurites métastatiques

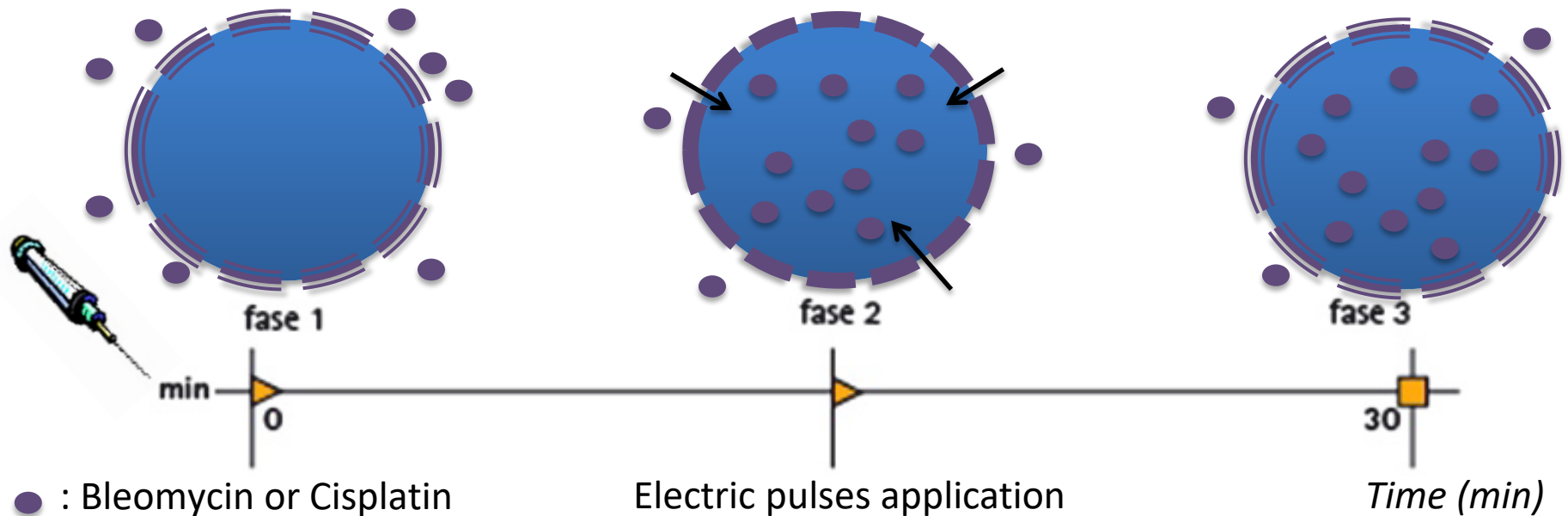
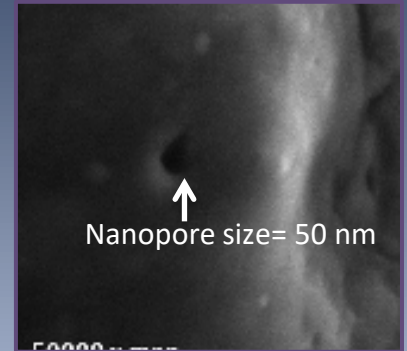
F. Deschamps



Electro-CHEMOTHERAPIE

Electrochemotherapy (ECT) refers to a combined treatment:

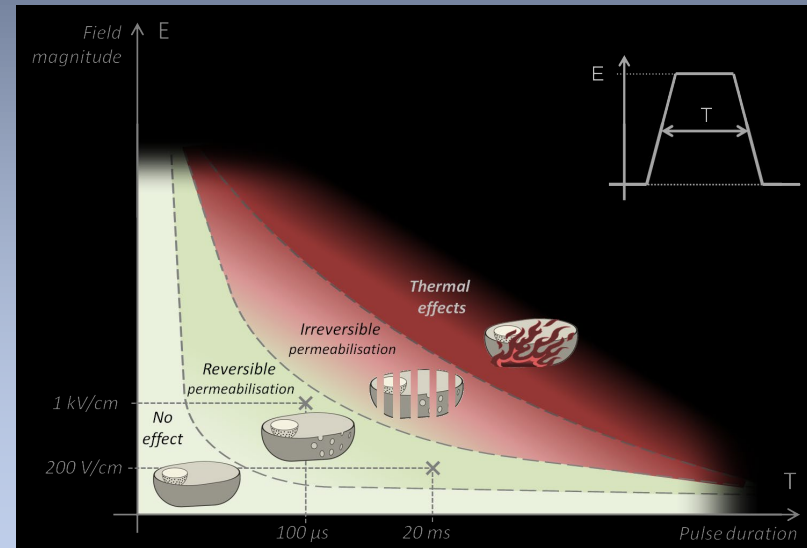
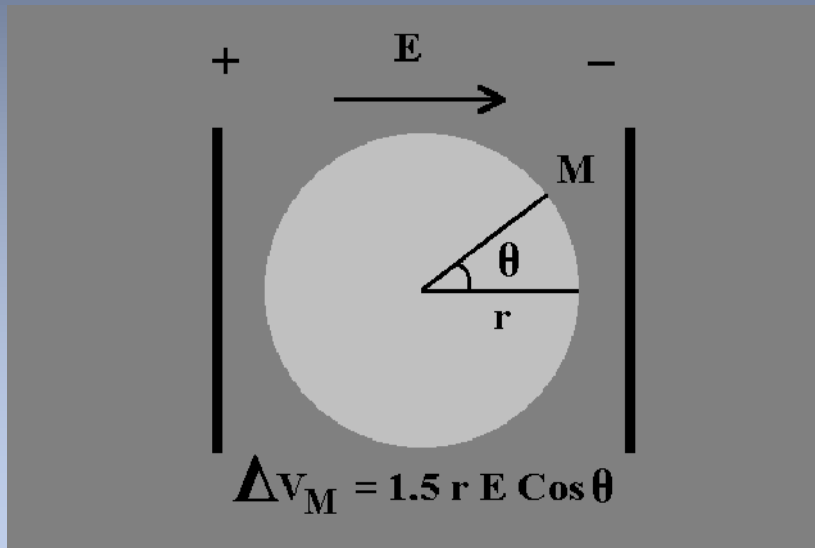
1. Reversible electroporation
2. IV administration of chemo to enhance its cytotoxic effect locally (up to 1000-fold for bleomycin).



Electro-CHEMOTHERAPIE

Electroporation:

- Phenomenon that occurs when cells are exposed to high-intensity electric pulses

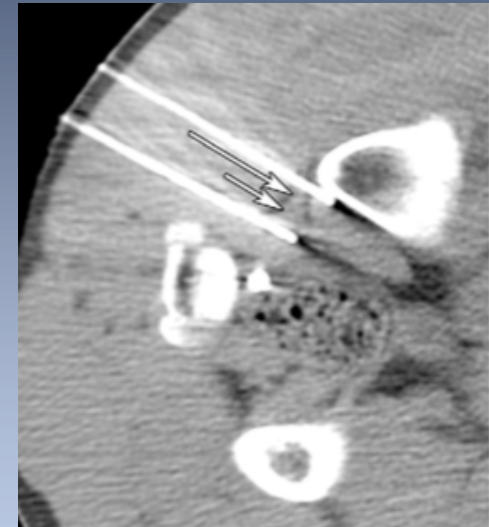

- Depending on electric pulse amplitude and number of pulses applied, electroporation can be reversible, with membrane permeability recovery, or irreversible, with loss of cell homeostasis and cell death.
- The electric field threshold is over 400 V/cm for reversible and over 800-1000 V/cm for IRE

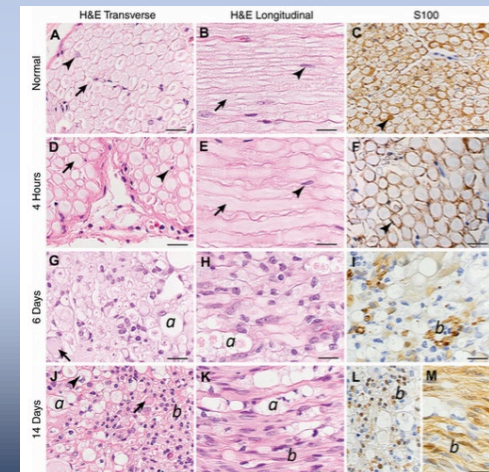
Electro-CHEMOTHERAPIE

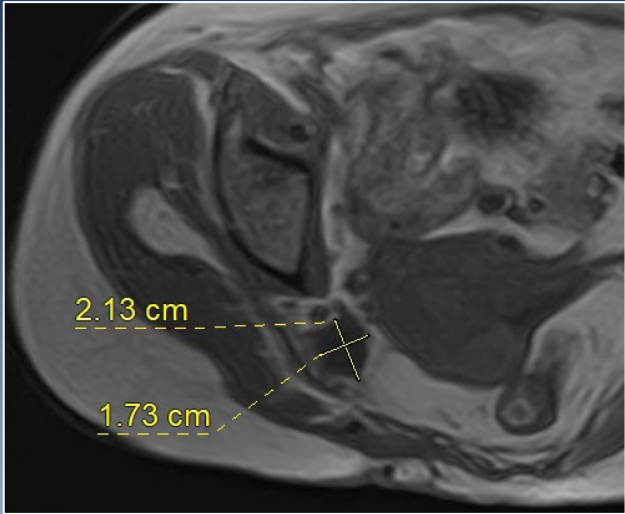
Electroporation close to the nerves???

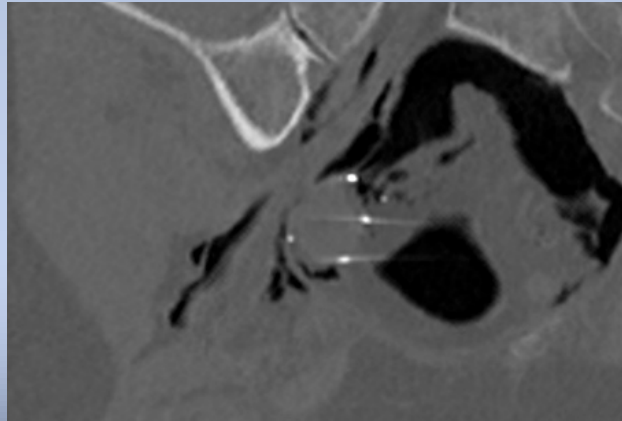
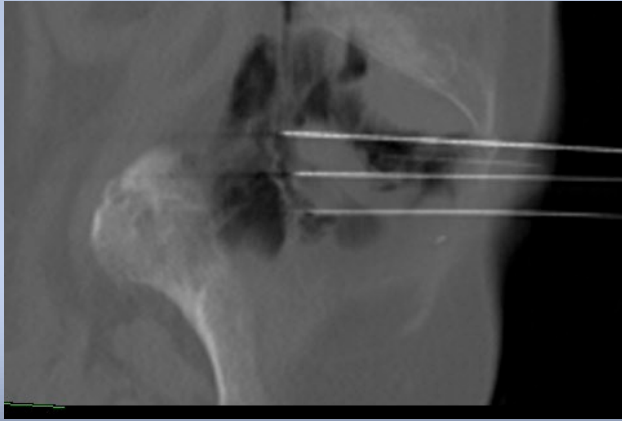
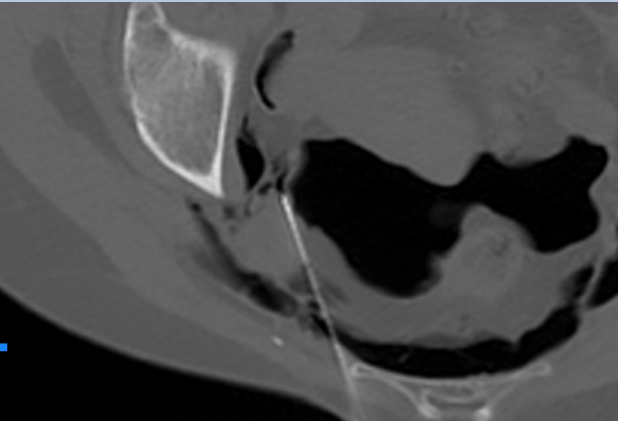
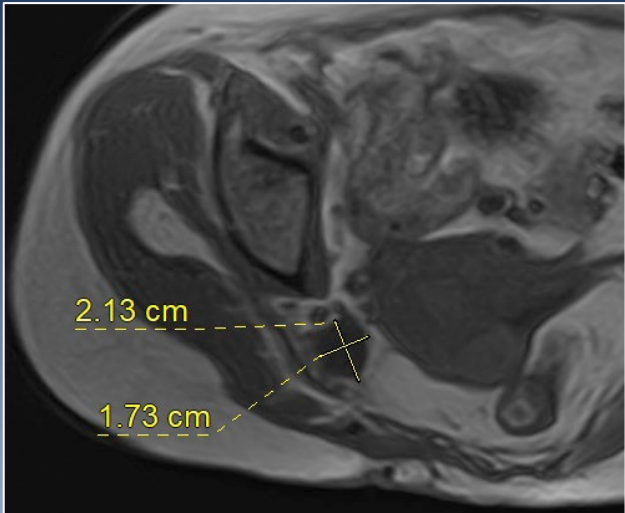
- IRE has the potential to damage nerves and may result in axonal swelling, fragmentation, and distal Wallerian degeneration.
- However, preservation of endoneurium architecture and proliferation of Schwann cells may suggest the potential for axonal regeneration.



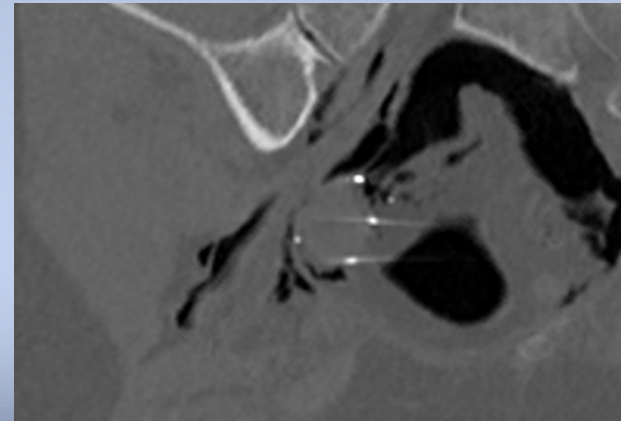
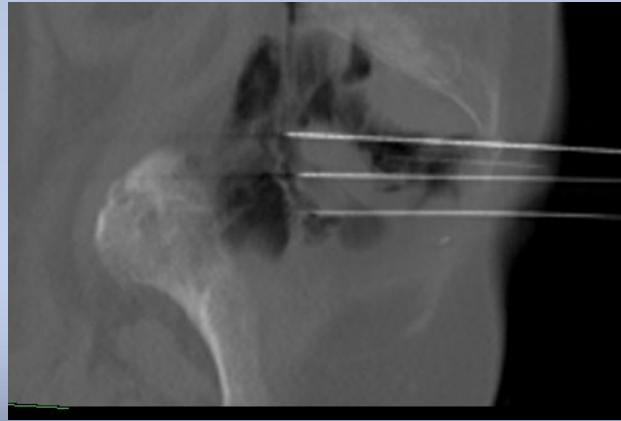
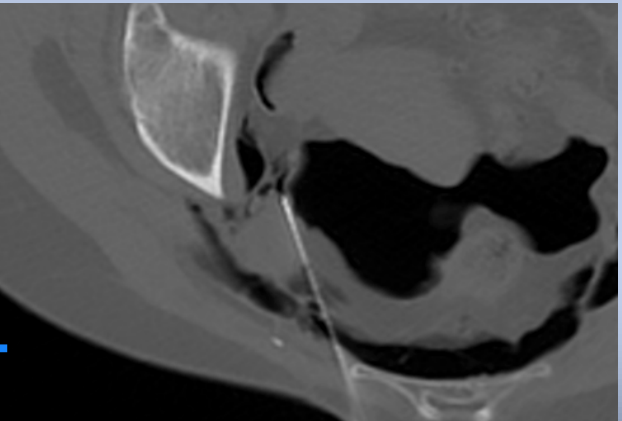
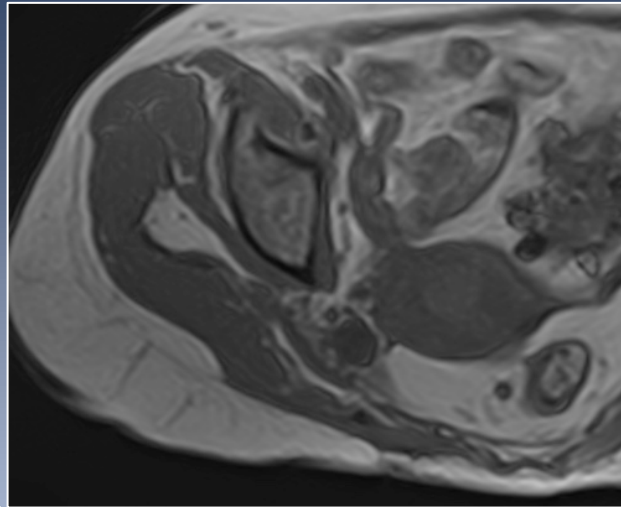
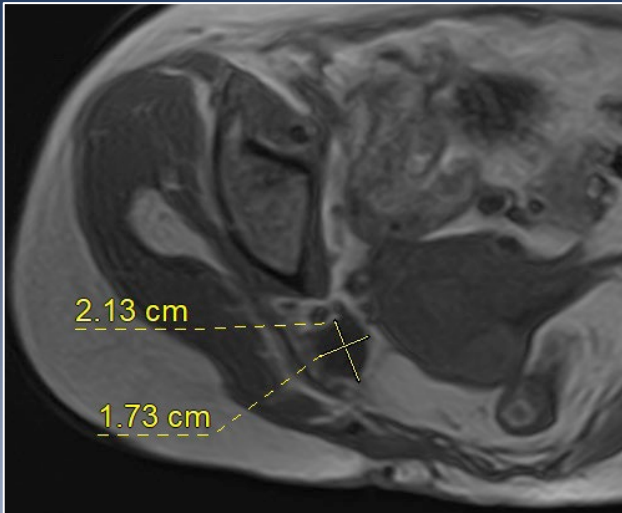
**Acute and Subacute Effects
of Irreversible Electroporation
on Nerves:** Experimental Study
in a Pig Model¹

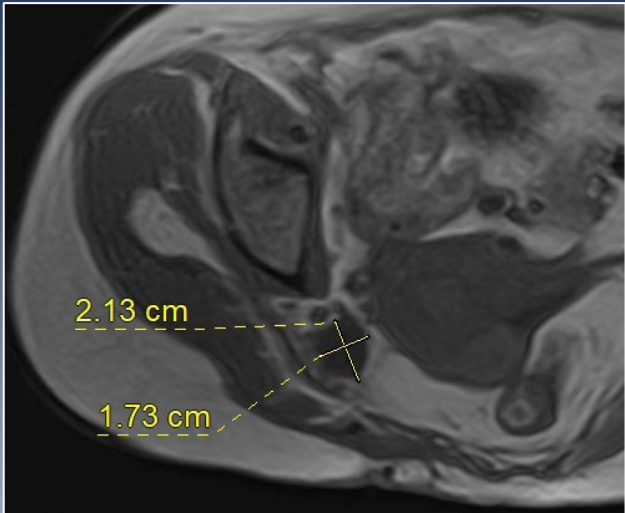




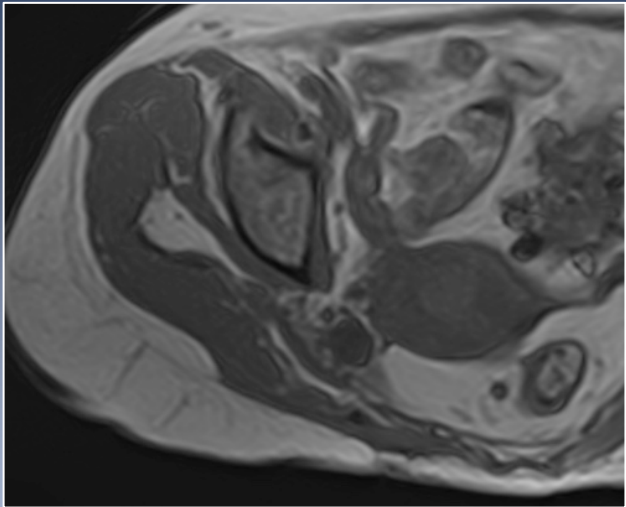


3 months

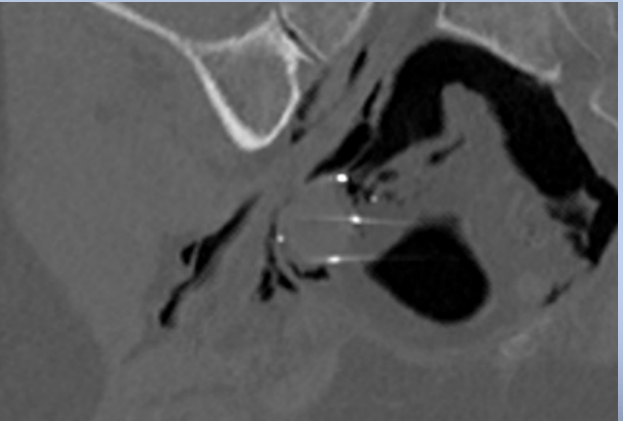
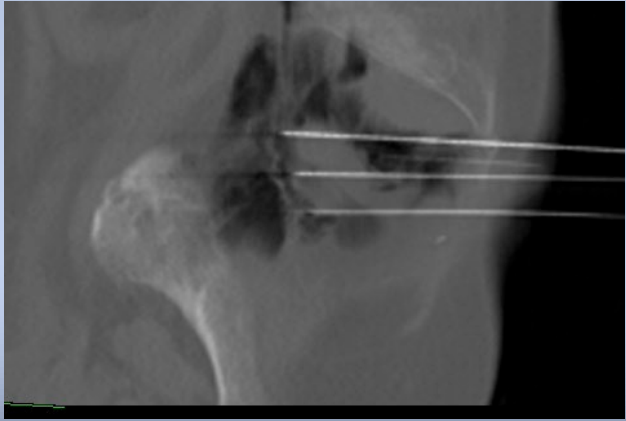
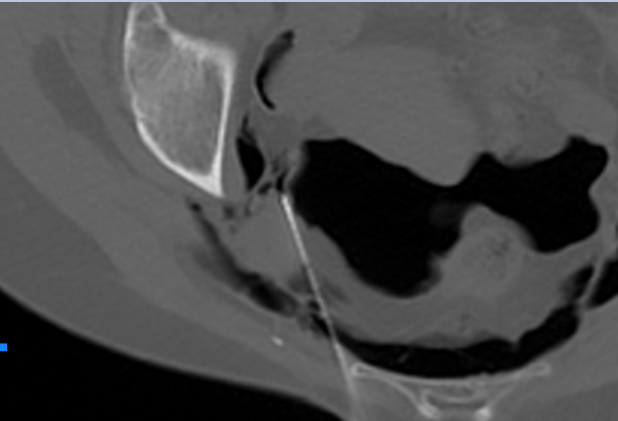
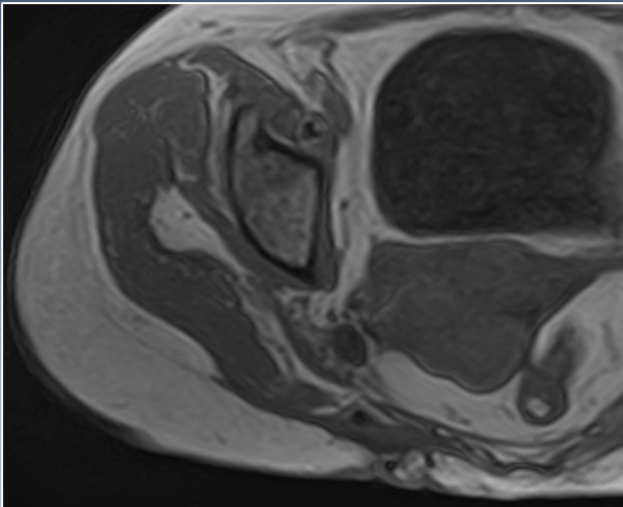


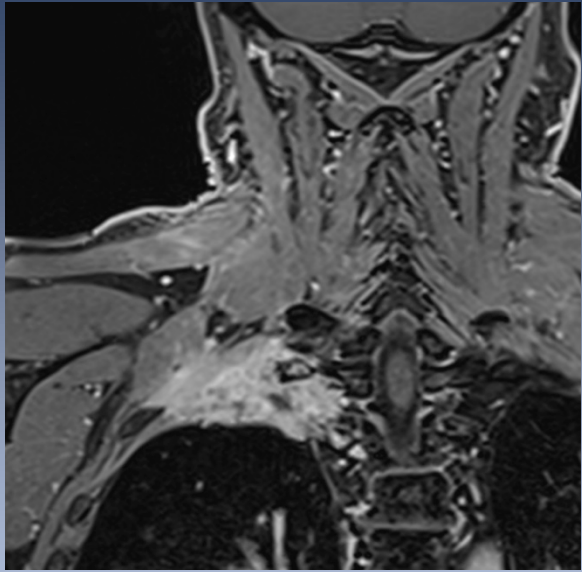


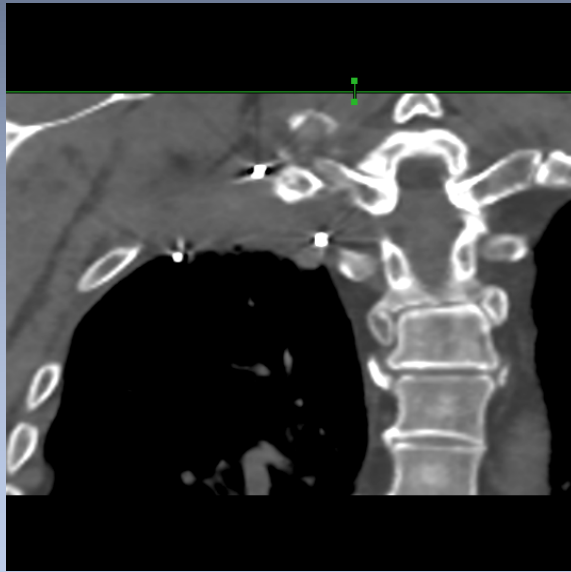
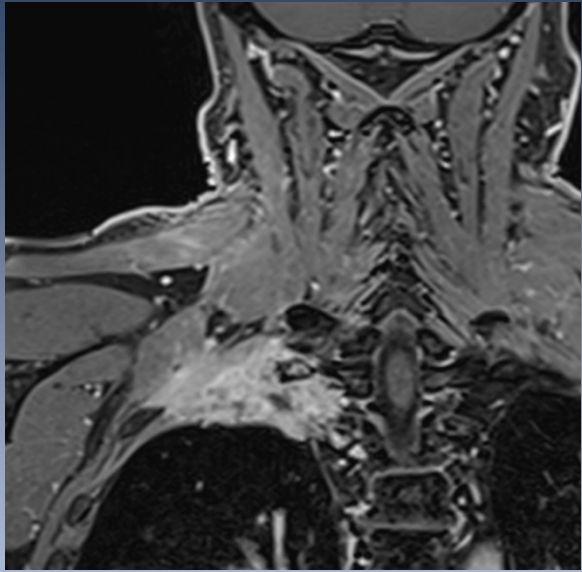
3 months

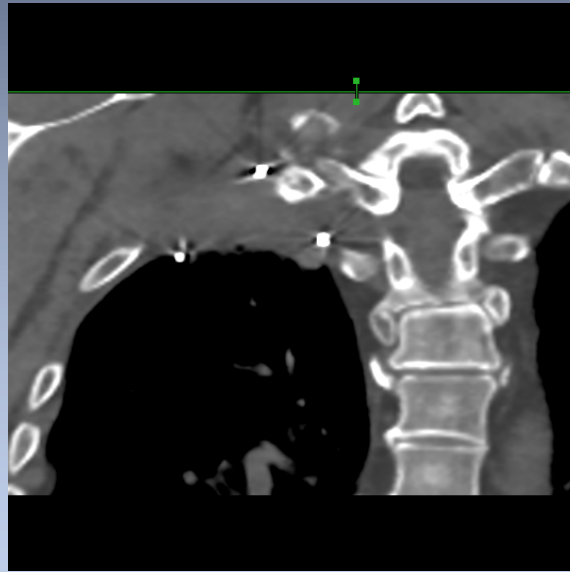
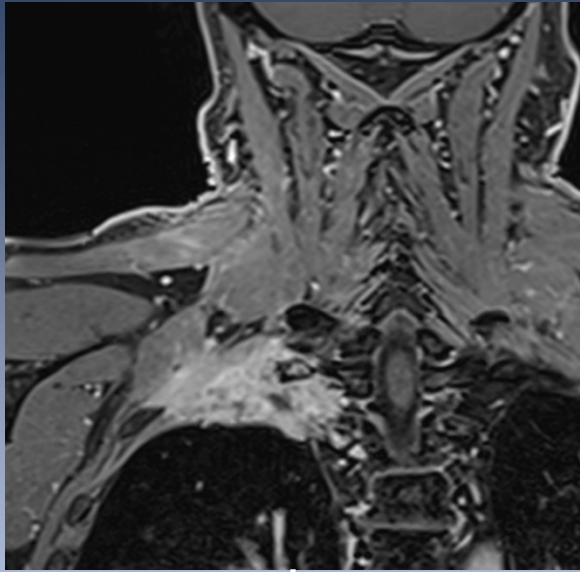


6 months

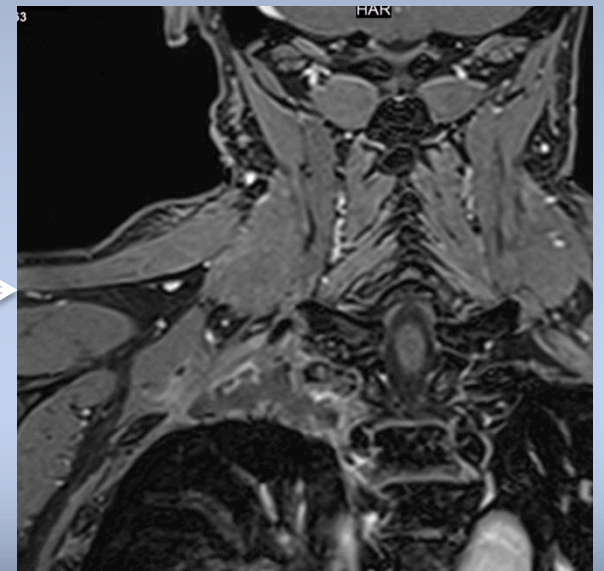

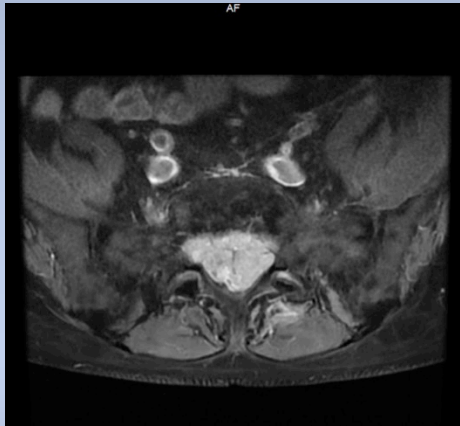

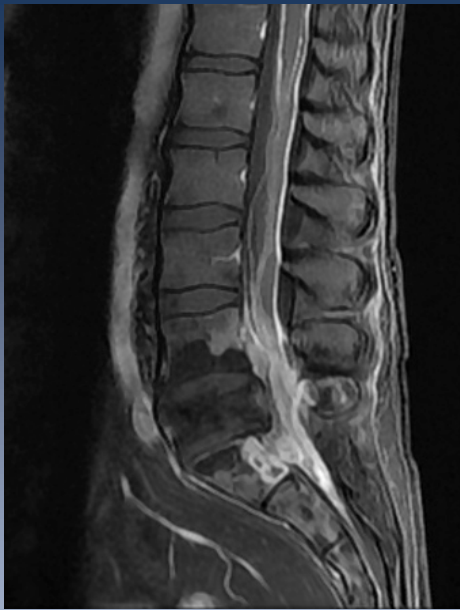
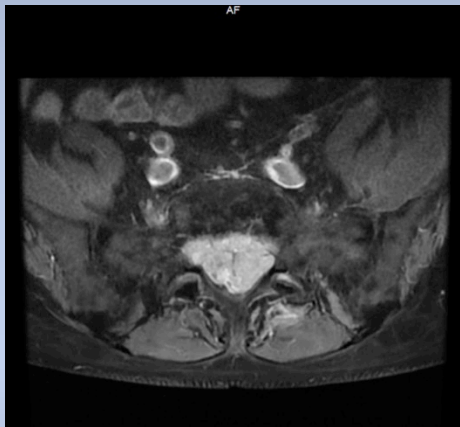
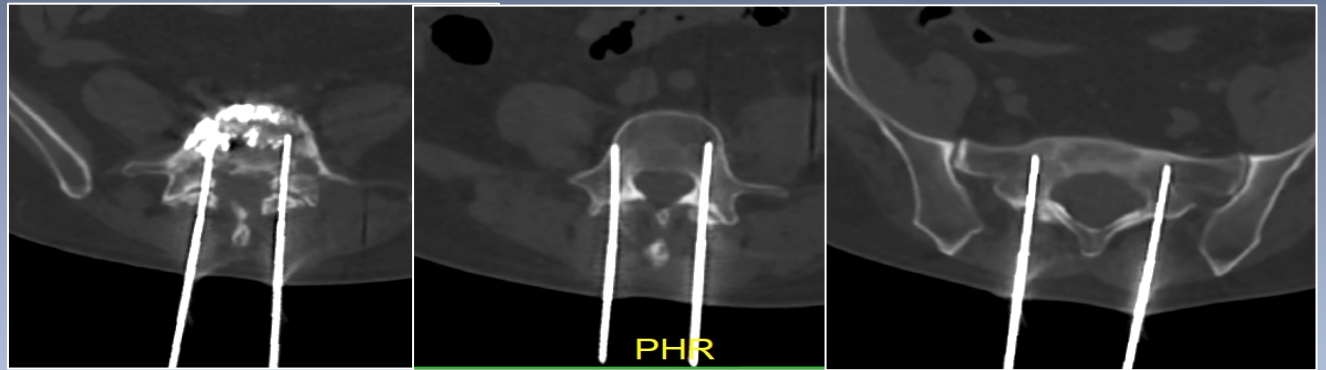


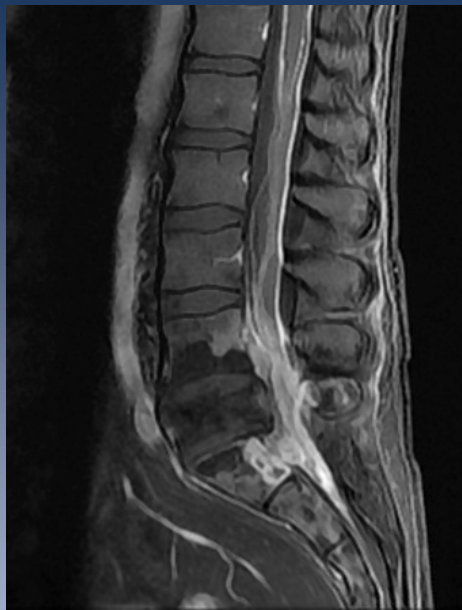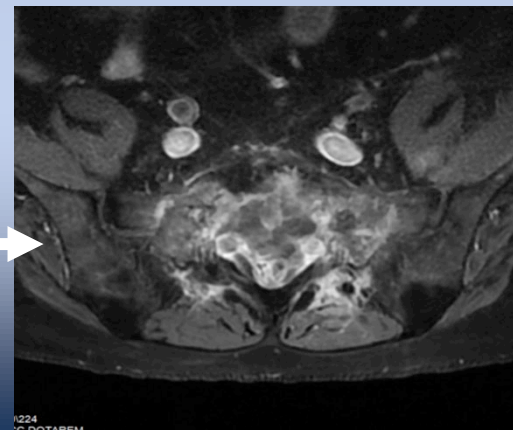
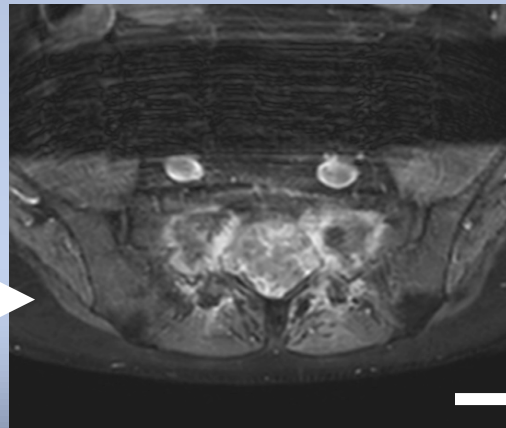
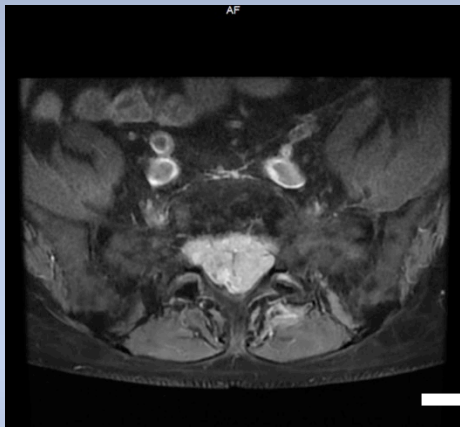
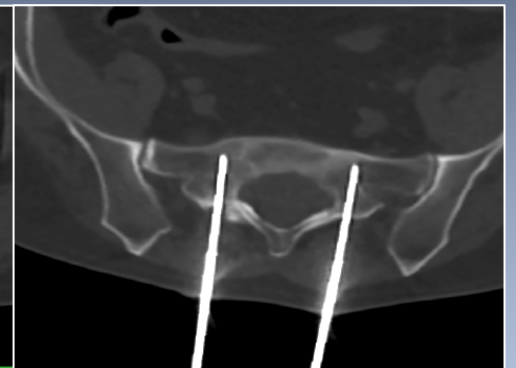
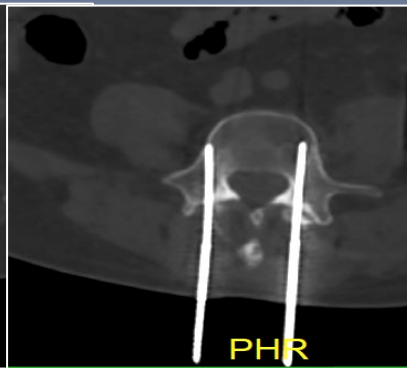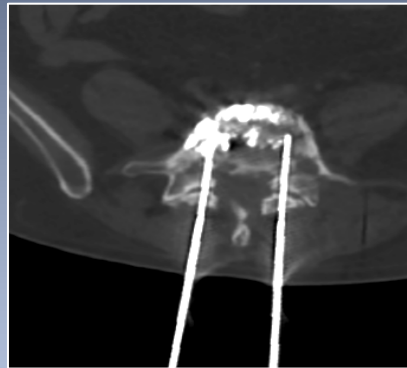


3 months









For Vertebral Metastases

WITH EXTENDED epidural involvement

→ decompression of spinal cord and neurological deficit

Review Article

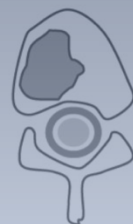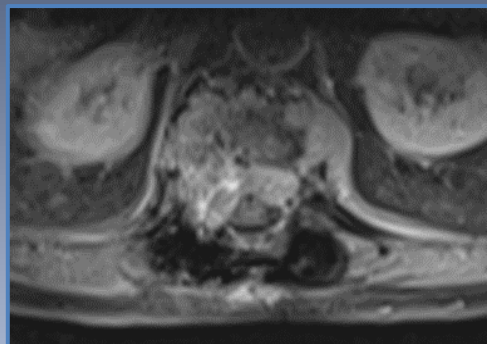
Radiat Oncol. J 2015;33(1):1-11
<http://dx.doi.org/10.3837/rnj.2015.33.1.1>
pISSN 2234-1900 eISSN 2234-3156

ROJ Radiation
Oncology
Journal

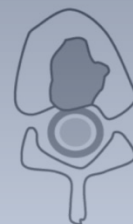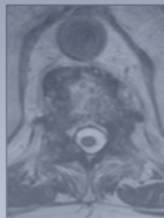
Contemporary treatment with radiosurgery for spine metastasis and spinal cord compression in 2015

Samuel Ryu, MD^{1,2}, Hannah Yoon, MD¹, Alexander Stessin, MD, PhD¹,
Fred Gutman, MD², Arthur Rosiello, MD², Raphael Davis, MD²

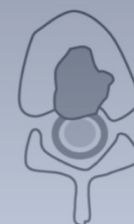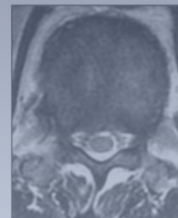
Epidural Spinal Cord Compression Scale (ESCCS)



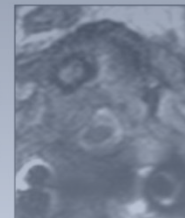
Grade 0
Bone involvement only
No canal compromise



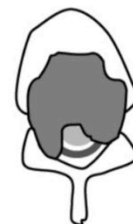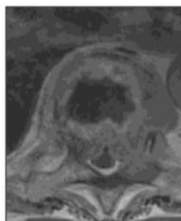
Grade I
Involvement of epidural fat



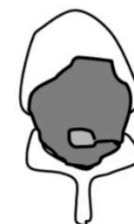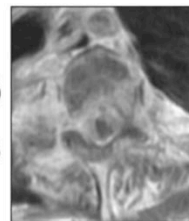
Grade II
Impingement of thecal sac



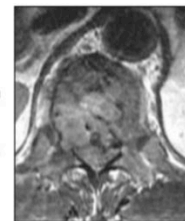
Grade III
Impingement of spinal cord



Grade IV
Compression and/or
displacement of spinal cord
Partial block of CSF



Grade V
Spinal cord compression and
Complete block of CSF



Thermal ablation
(Cryo/ RFA/ MWA)

SBRT
(Stereotactic Body Radiation Therapy)

cEBRT +/- decompressive surgery
(conventional External Beam Radiation Therapy)

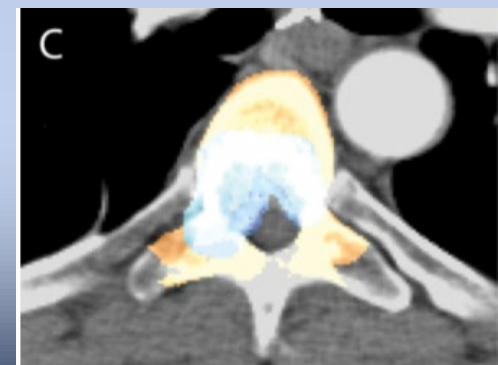
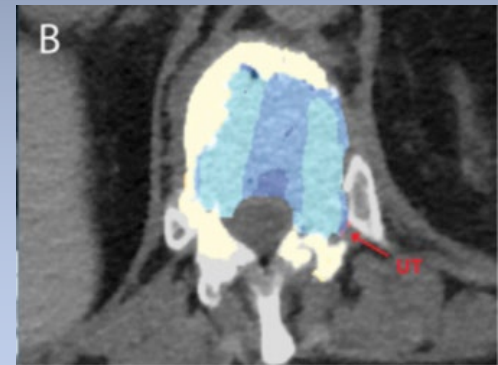
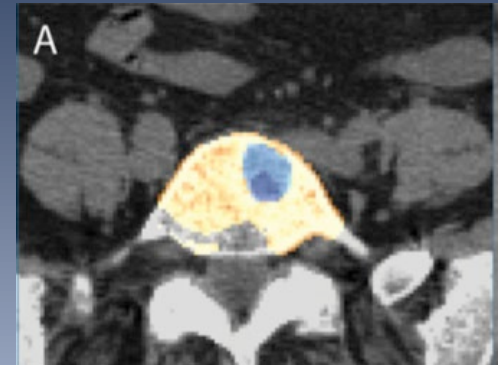
grade 3 : impingement of the spinal cord
grade 4 : partial spinal cord compression and displacement
grade 5 : spinal cord compression with cerebrospinal fluid not visible

Electro-CHEMOTHERAPIE

Electroporation close to the spinal cord???


Electric field distribution in vertebral tumor and surrounding tissues in 3 representative clinical cases of spinal metastases, including one with epidural extension at T6 (c)

- 100% tumor coverage was obtained
- Hypothetical damage to spinal cord and nerves for tumor located in the spinal canal, the spinal cord was covered with electric field above the assumed irreversible threshold (>800 V/cm).



Original Article

Electrochemotherapy of Spinal Metastases Using Transpedicular Approach—A Numerical Feasibility Study

Helena Cindrič, BSc¹, Bor Kos, PhD¹ , Giuseppe Tedesco, MD², Matteo Cadossi, MD, PhD², Alessandro Gasbarrini, MD², and Damijan Miklavčič, PhD¹

Technology in Cancer Research & Treatment
Volume 17: 1-13
© The Author(s) 2018
Reprints and permission:
sagepub.com/journalsPermissions.nav
DOI: 10.1177/1533034618770253
journals.sagepub.com/home/tcr



Tumor - UT ($E < 400$ V/cm)

Tumor - RE ($E > 400$ V/cm)

Tumor - RE ($E > 600$ V/cm)

Tumor - IRE ($E > 800$ V/cm)

Bone - RE ($E > 400$ V/cm)

Electro-CHEMOTHERAPIE

Electroporation close to the spinal cord???

Transient interstitial edema and vacuolization at early experimental times in sheep spinal nerves and spinal cord were noted...

... but there were no permanent functional deficits attributable to the IRE, thus showing the feasibility of electroporation in the spine

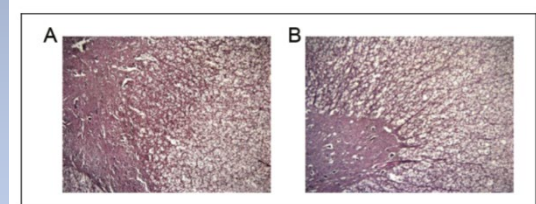
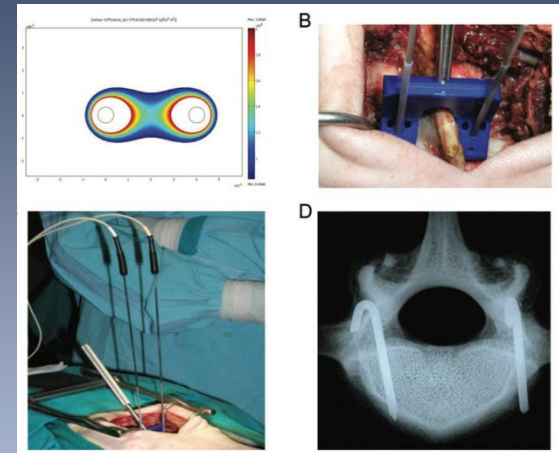


Figure 13. Histological sections of spinal cord ($\times 10$ magnification; hematoxylin-eosin staining). A, Untreated spinal cord. B, electro-poration (EP)-treated spinal cord: myelin sheath with increased vacuolation.

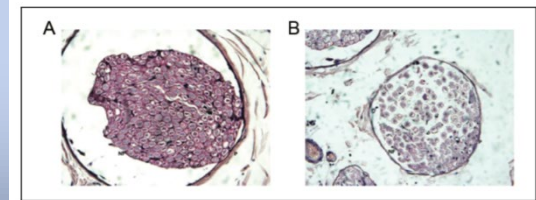


Figure 14. Histological sections of spinal nerve ($\times 40$ magnification; hematoxylin-eosin staining). A, Untreated spinal nerve. B, Electro-poration (EP)-treated spinal nerve: disorganization of nerve fibres. A large number of myelin sheaths have lost their granular structure. P indicates perineurium; NF, nerve fibres.

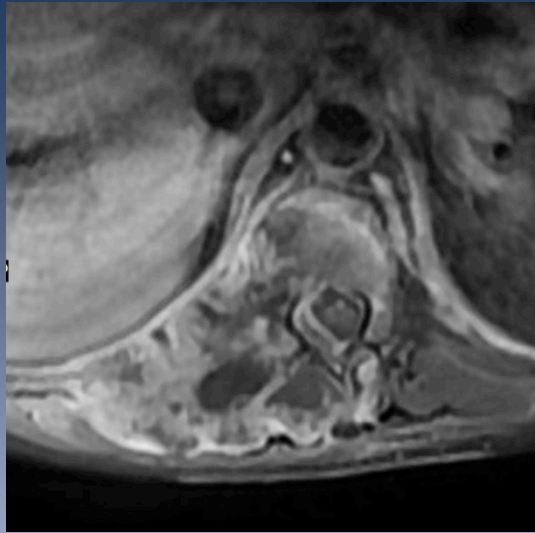
Original Article

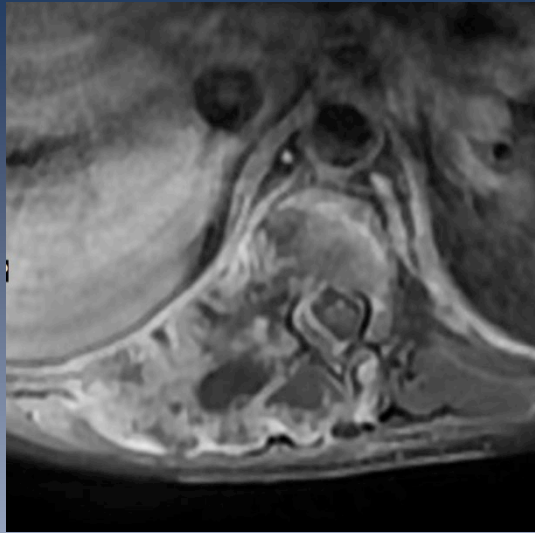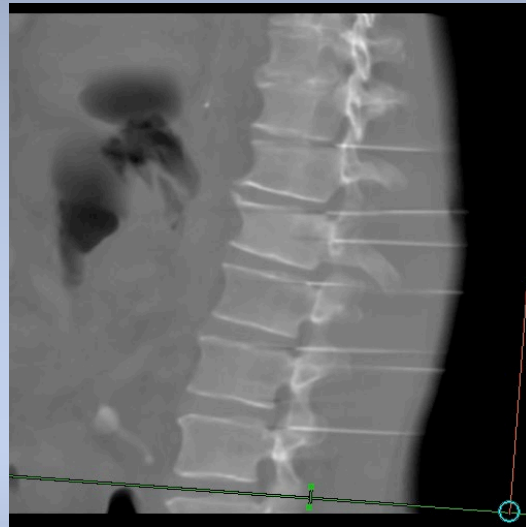
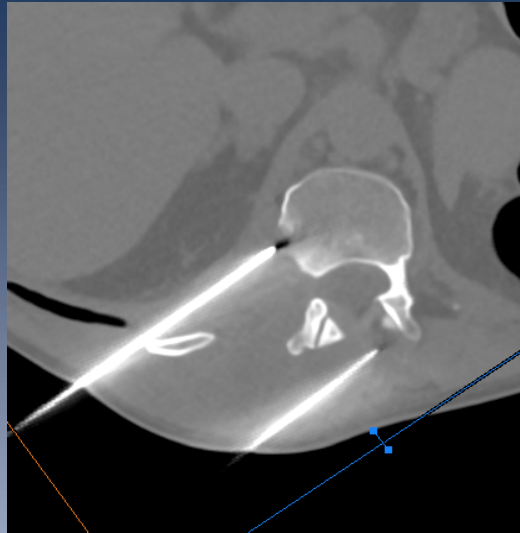Feasibility of Electroporation in Bone and in the Surrounding Clinically Relevant Structures: A Preclinical Investigation

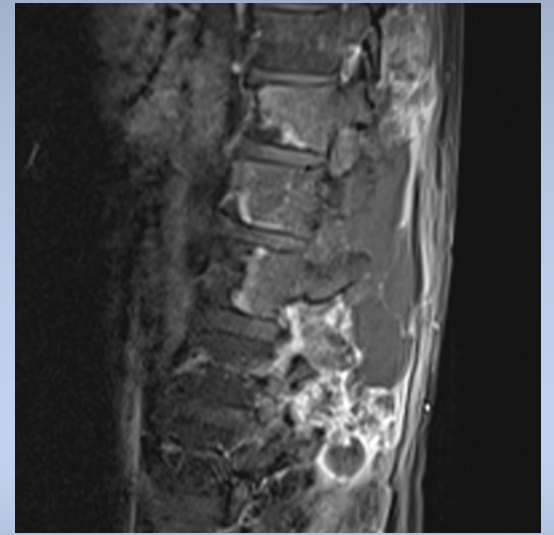
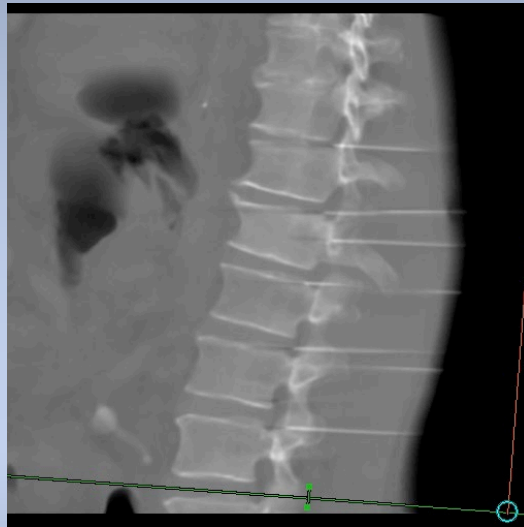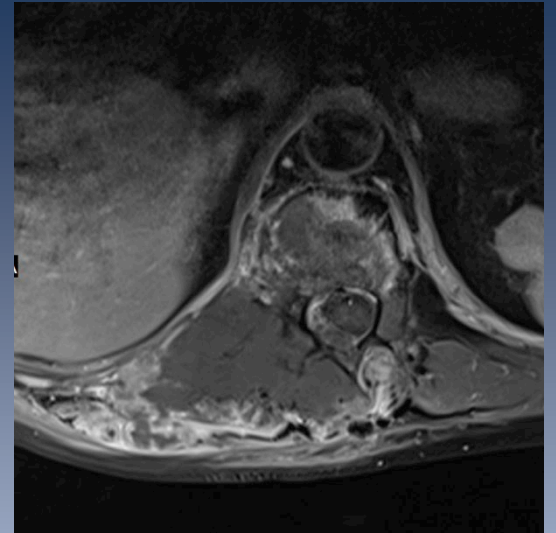
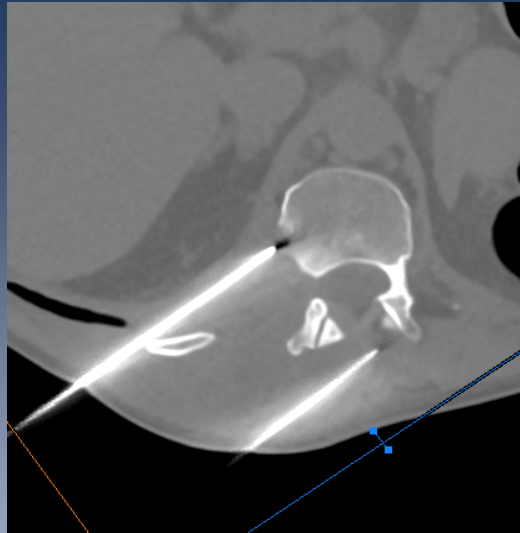
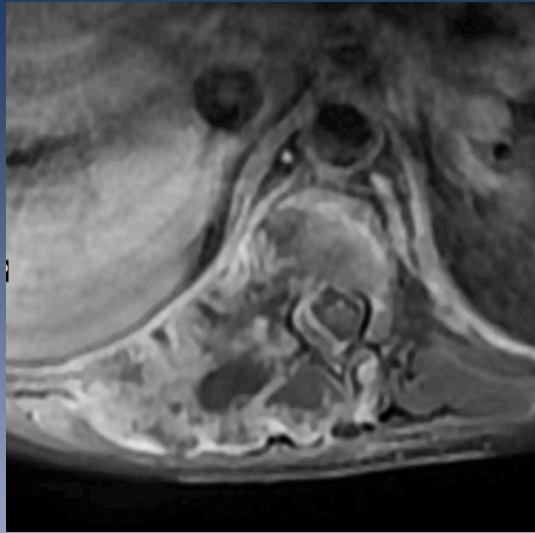
Matilde Tschon, PhD^{1,2}, Francesca Salamanna, PhD²,
Mattia Ronchetti, BSc³, Francesco Cavani, BSc⁴,
Alessandro Gasbarrini, MD⁵, Stefano Boriani, MD⁵,
and Milena Fini, MD^{1,2}

Technology in Cancer Research & Treatment
1–12
© The Author(s) 2015
Reprints and permission:
sagepub.com/journalsPermissions.nav
DOI: 10.1177/1533034615604454
tct.sagepub.com
SAGE

Technology in Cancer Research & Treatment 2015



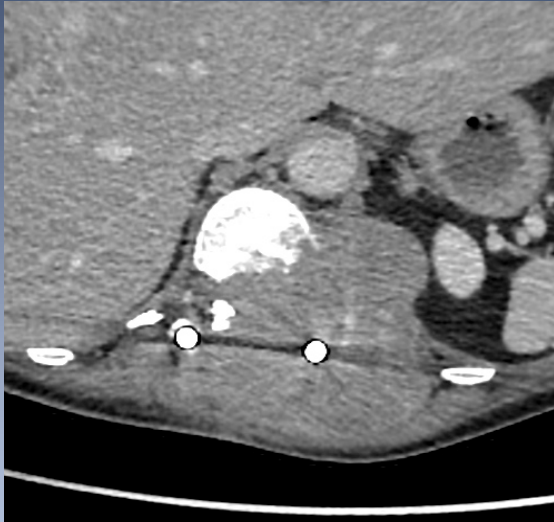



Article

Electrochemotherapy Is Effective in the Treatment of Bone Metastases

Laura Campanacci ¹, Luca Cevolani ^{1,*}, Francesca De Terlizzi ², Laura Saenz ³, Nikolin Ali ¹, Giuseppe Bianchi ¹ and Davide Maria Donati ¹



Cardiovasc Intervent Radiol
https://doi.org/10.1007/s00270-019-02316-4

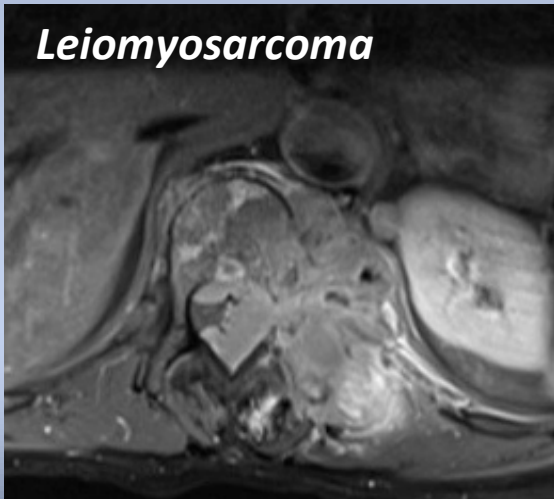
C RSE

CASE REPORT

Percutaneous Image-Guided Electrochemotherapy of Spine Metastases: Initial Experience

François H. Cornelis ¹, Mohamed Ben Ammar ¹, Maud Nouri-Neuville ¹, Lise Matton ², Marc Antoine Benderra ³, Joseph Gligorov ³, Vincent Fallet ², Luis M. Mir ⁴

Leiomyosarcoma

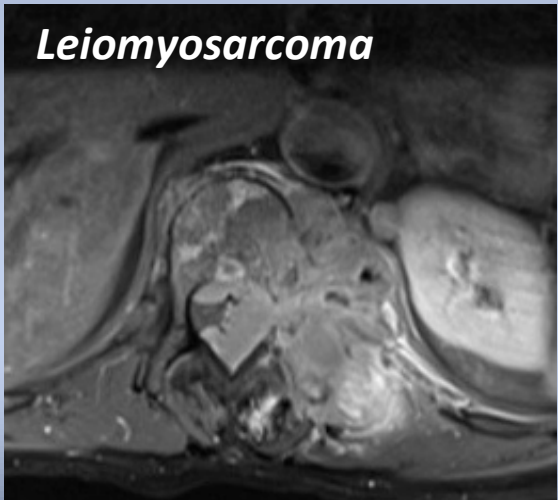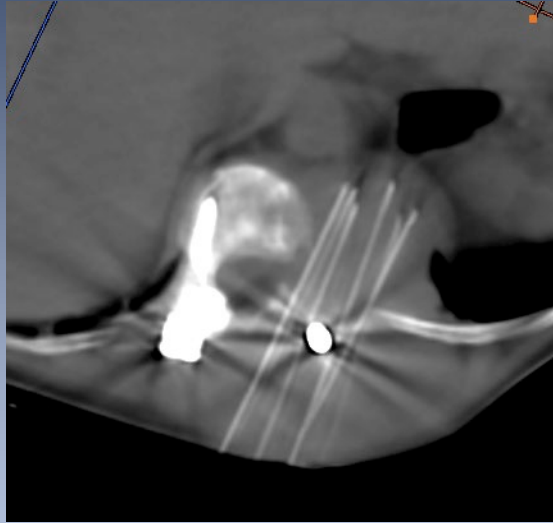
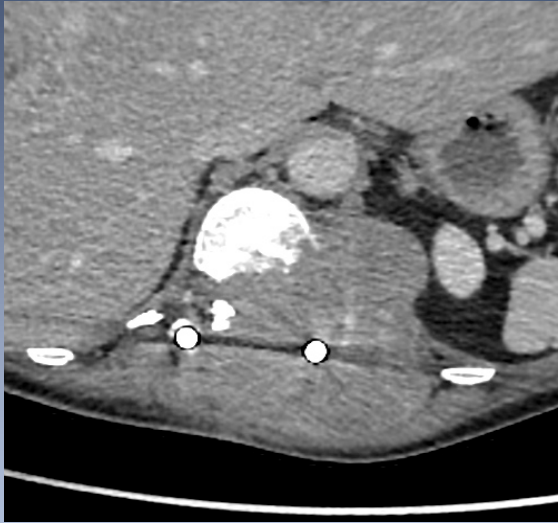


Salvage Electro-CHEMOTHERAPIE???




Spinal cord compression (epidural extension grade 5)
despite cEBRT and surgical decompression

Electro-CHEMOTHERAPIE ???



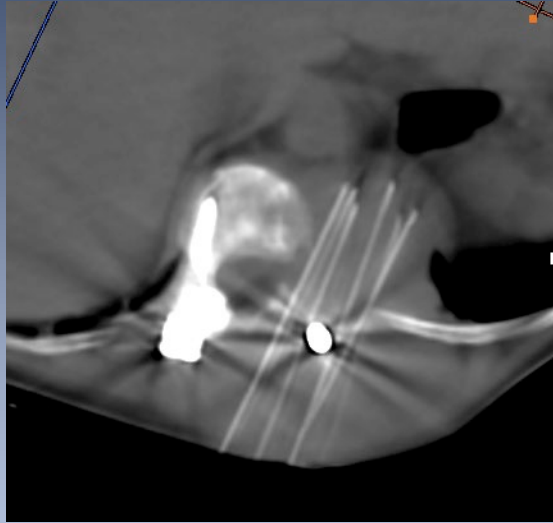
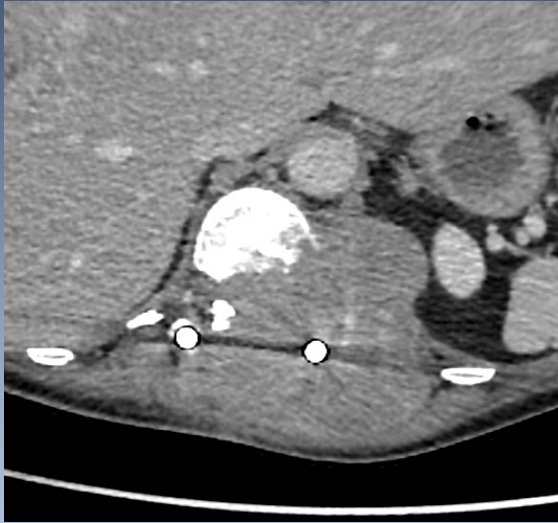
Leiomyosarcoma



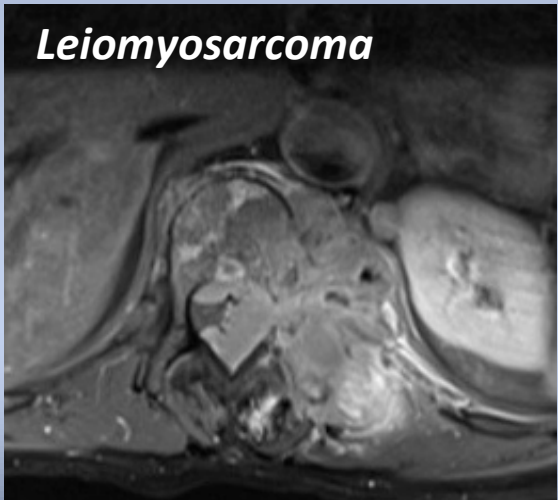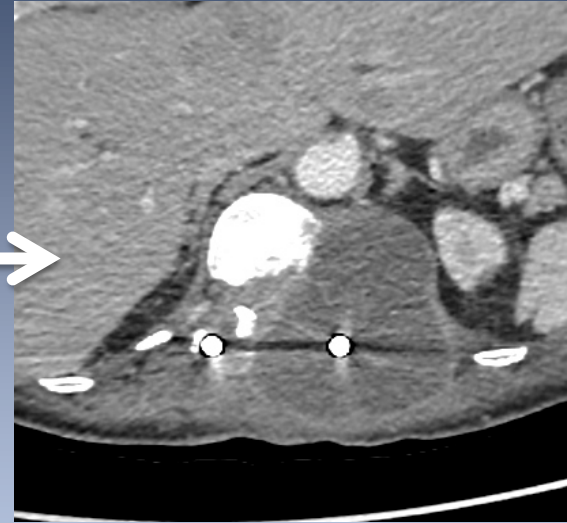Spinal cord compression (epidural extension grade 5)
despite cEBRT and surgical decompression




Electro-CHEMOTHERAPIE !!!



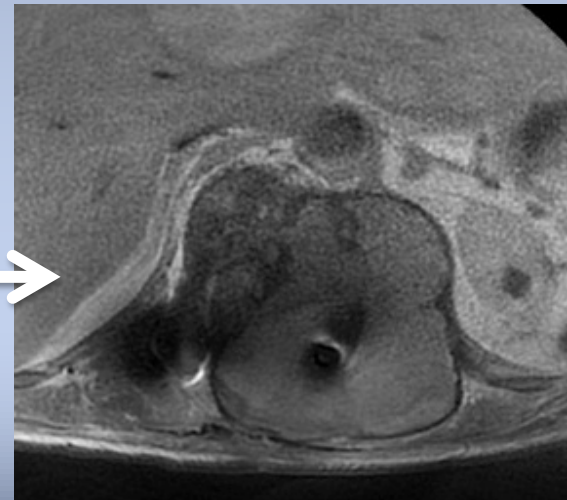
3 months



Leiomyosarcoma



3 months



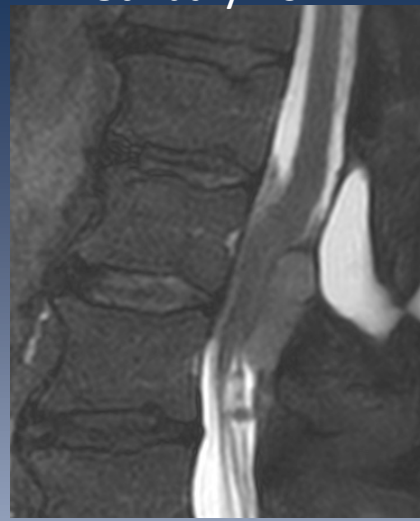
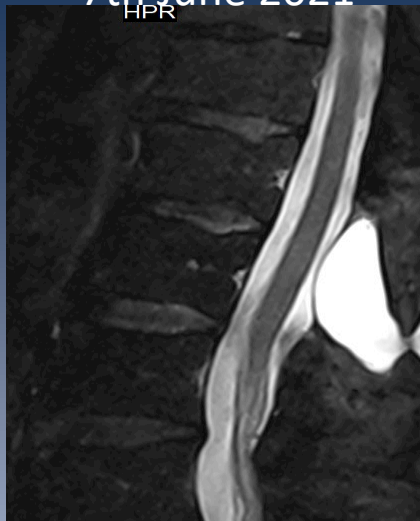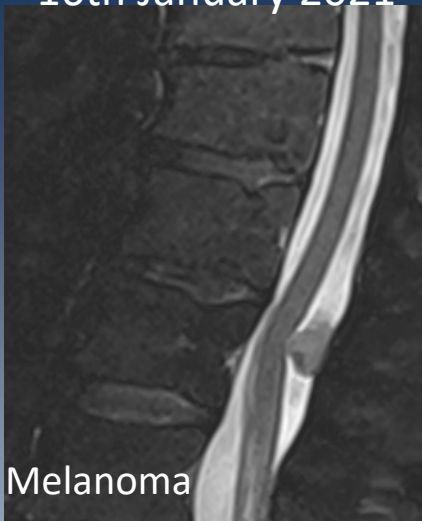
Spinal cord compression (epidural extension grade 5)
despite cEBRT and surgical decompression

- ✓ *Neurological improvement +++*
- ✓ *Pain relief +++*

16th January 2021

7th June 2021

8th July 2021

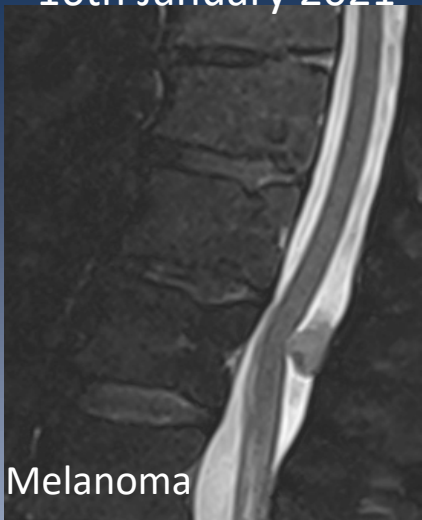


Recurrence M+6 SBRT

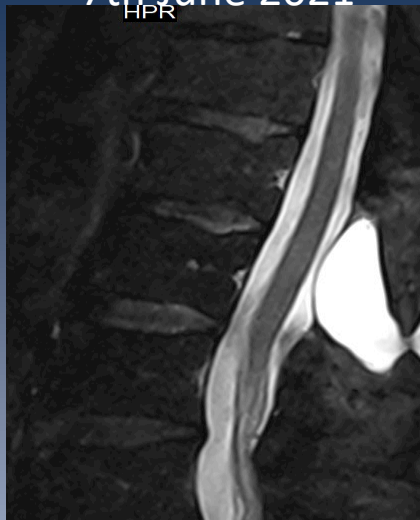Surgical resection

Recurrence M+1 Surgery

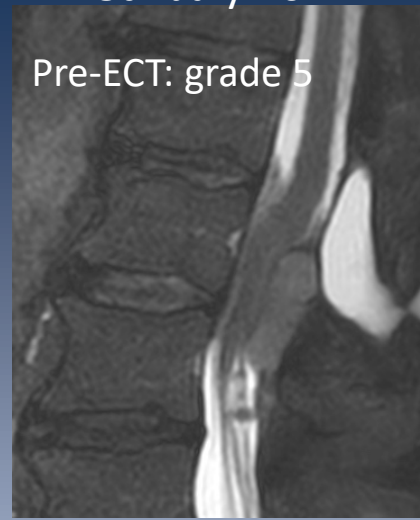16th January 2021



7th June 2021



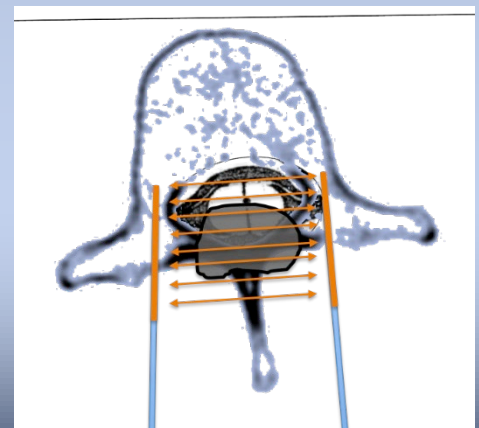
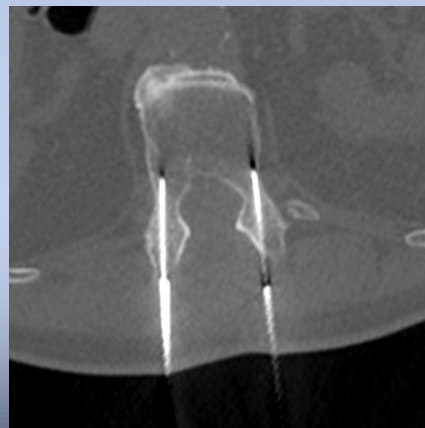
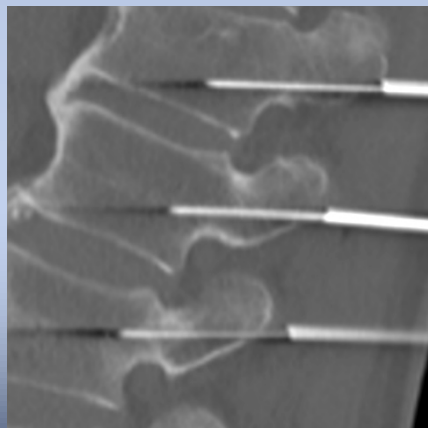
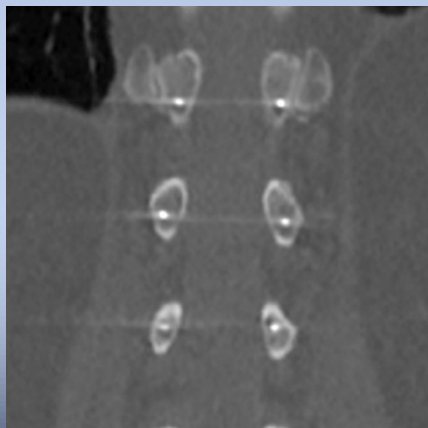
8th July 2021



Recurrence M+6 SBRT

Surgical resection

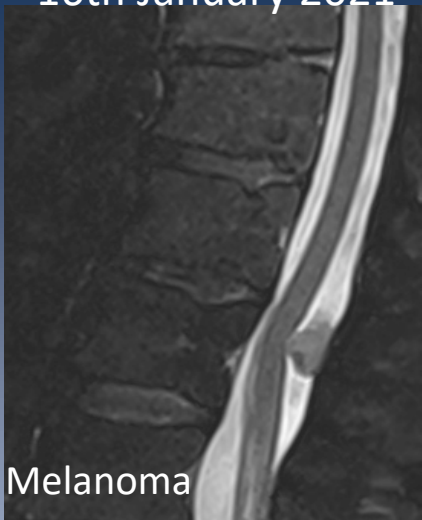
Recurrence M+1 Surgery



Electrochemotherapy:

13th July 2021

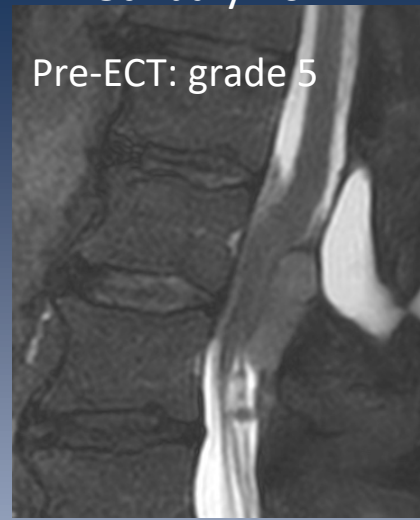16th January 2021



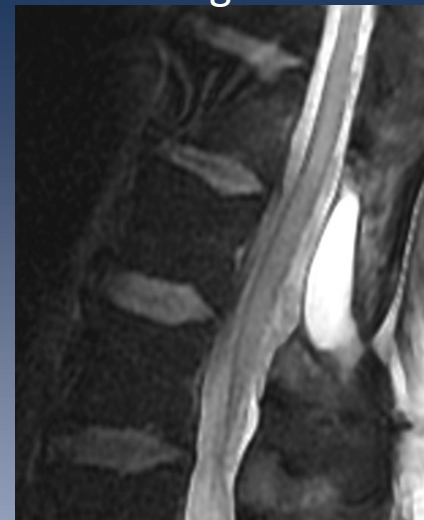7th June 2021



8th July 2021



24th August 2021

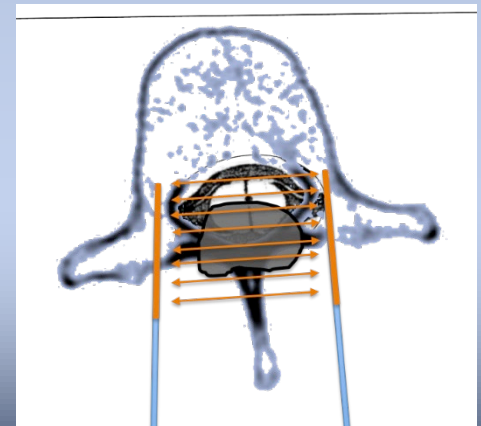
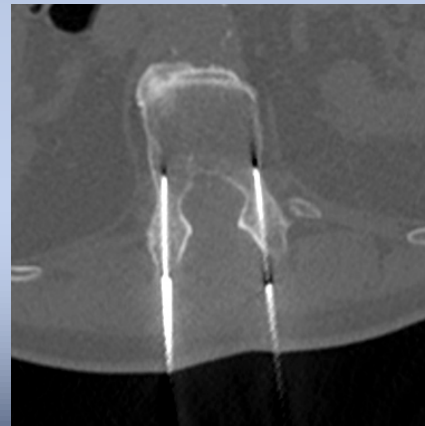
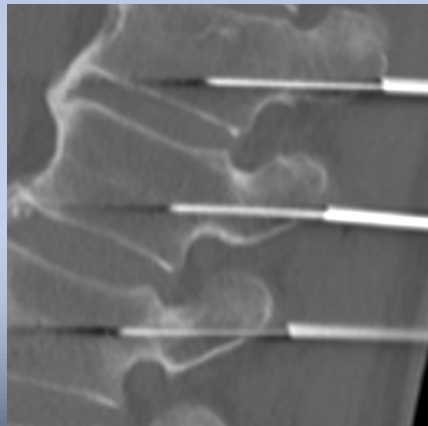
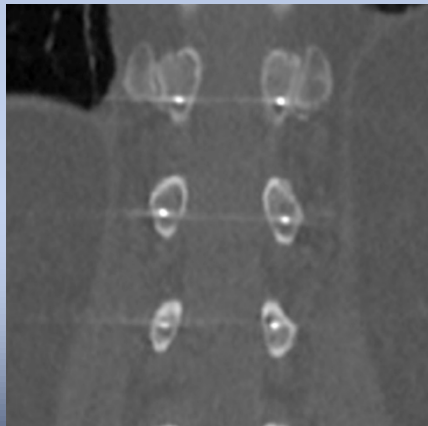


Recurrence M+6 SBRT

Surgical resection

Recurrence M+1 Surgery

M+1: grade 0



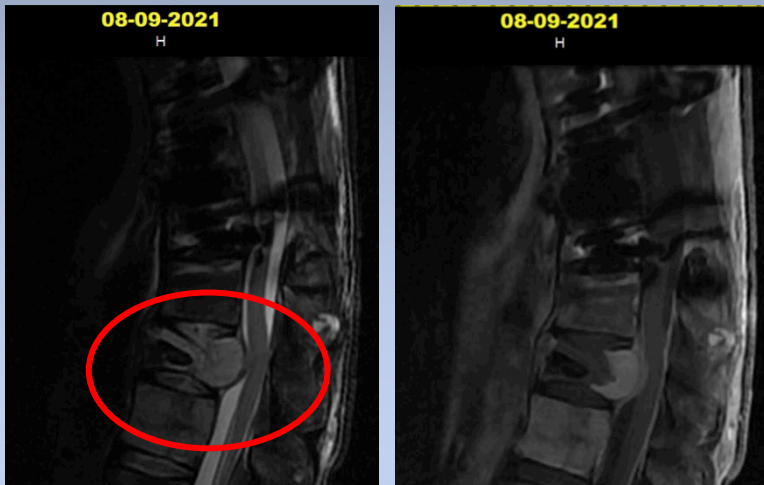
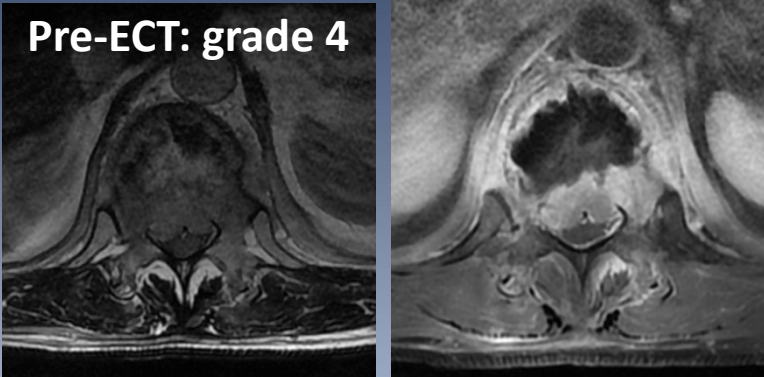
Electrochemotherapy:

13th July 2021

39 yo, Paraganglioma

T12, progressive despite cEBCT (and cement)

Pre-ECT: grade 4



???

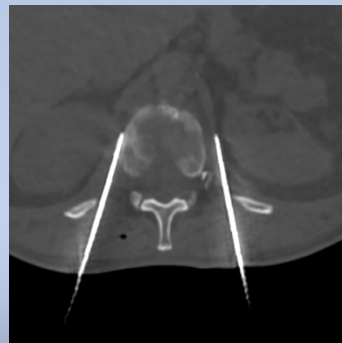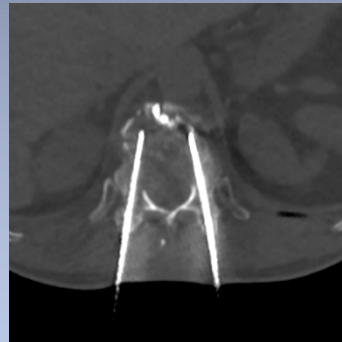
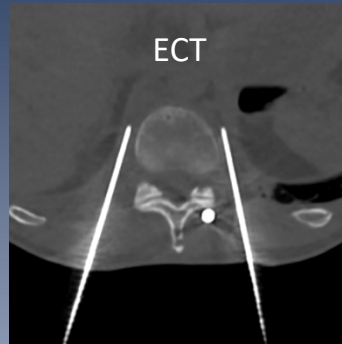
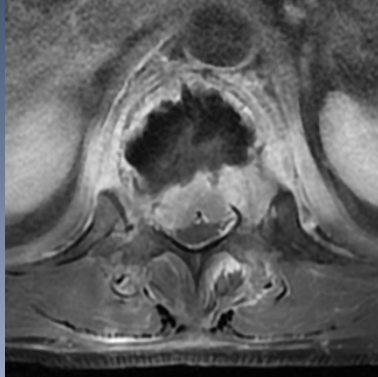
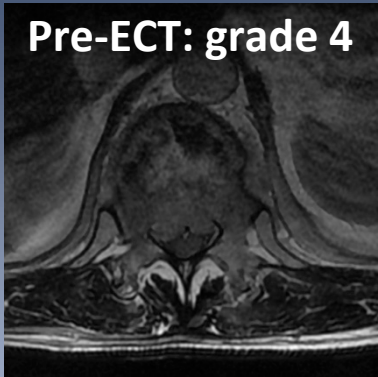


39 yo, Paraganglioma

T12, progressive despites cEBCT

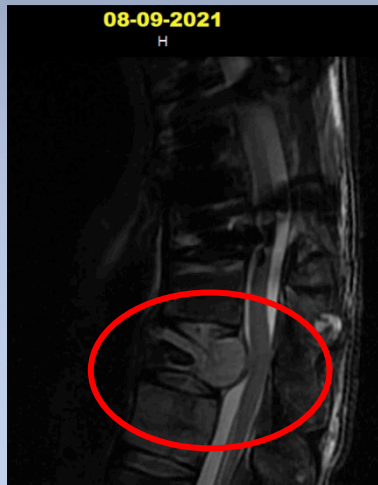09/09/2021

Pre-ECT: grade 4



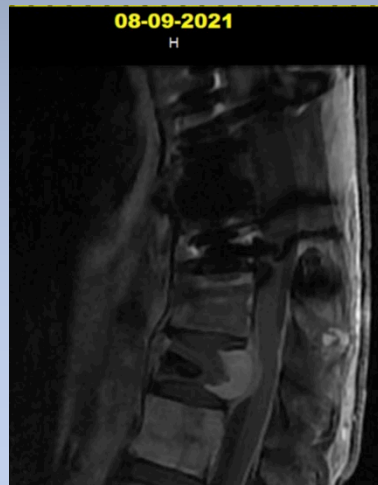
08-09-2021

H



08-09-2021

H



39 yo, Paraganglioma

T12, progressive despite cEBCT

09/09/2021

M+1: grade 1

Pre-ECT: grade 4

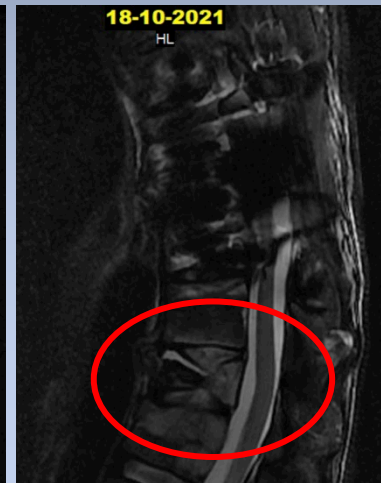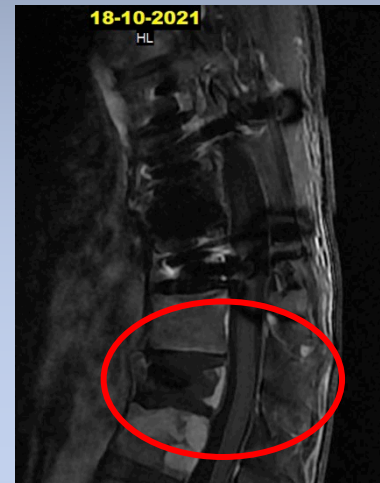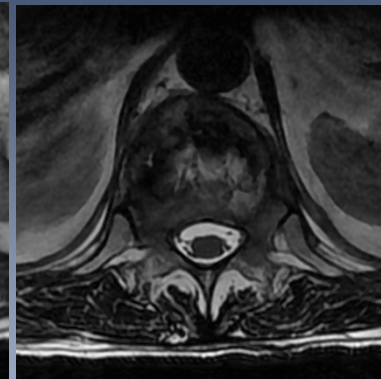
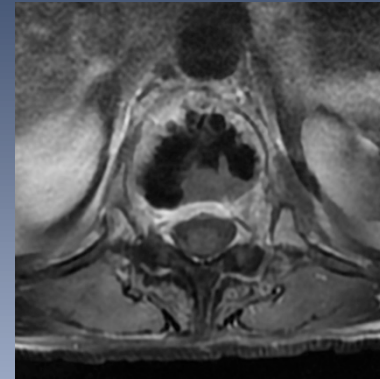
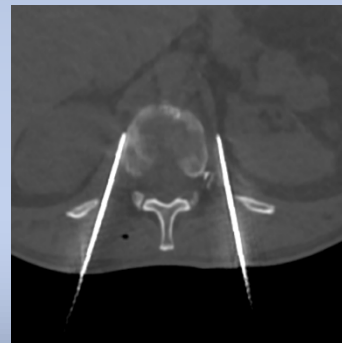
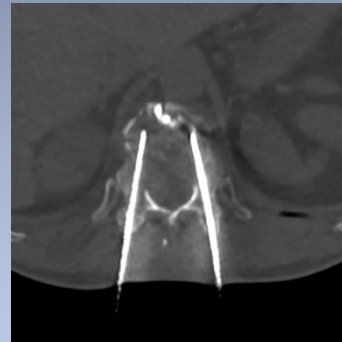
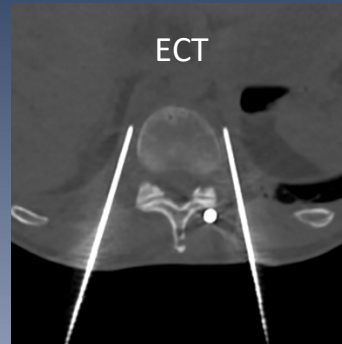
ECT

08-09-2021
H

08-09-2021
H

18-10-2021
HL

18-10-2021
HL



39 yo, Paraganglioma

T12, progressive despite cEBCT

09/09/2021

Pre-ECT: grade 4

ECT

M+1: grade 1

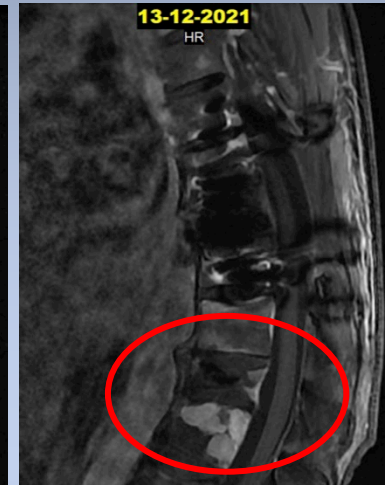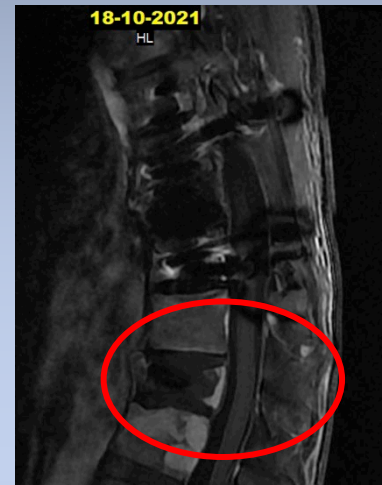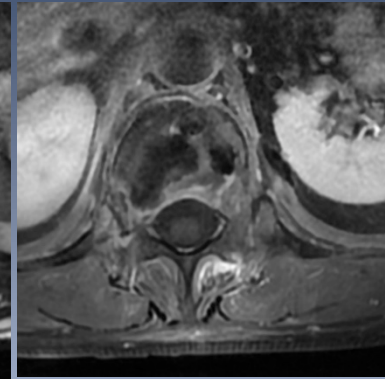
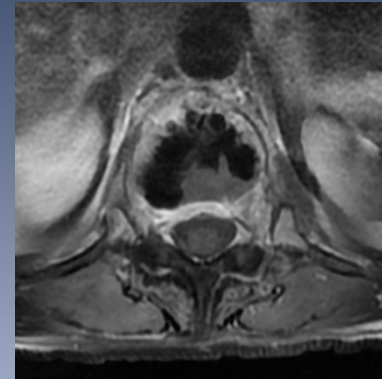
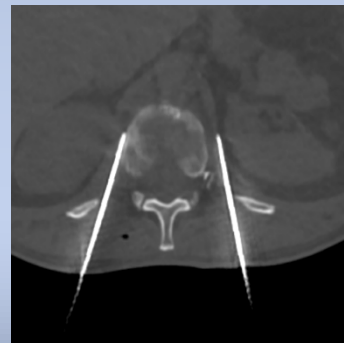
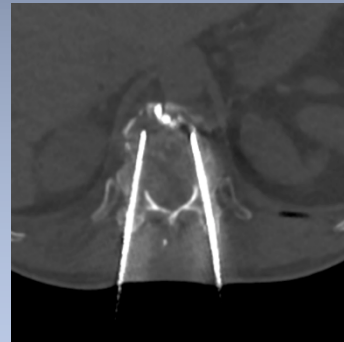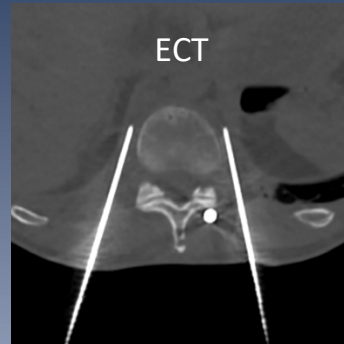
M+3: grade 0

08-09-2021
H

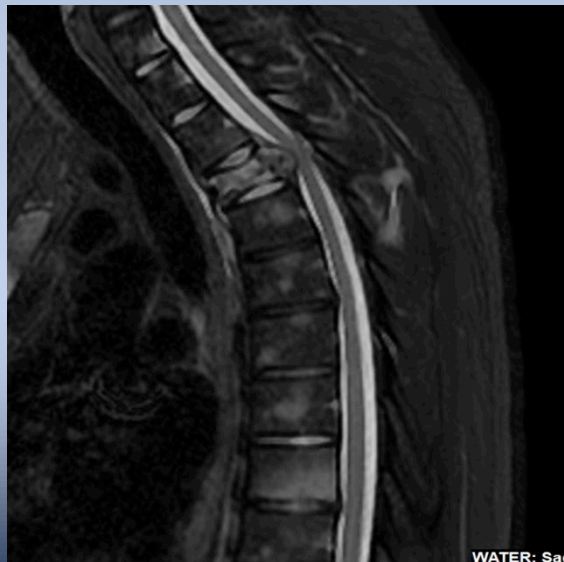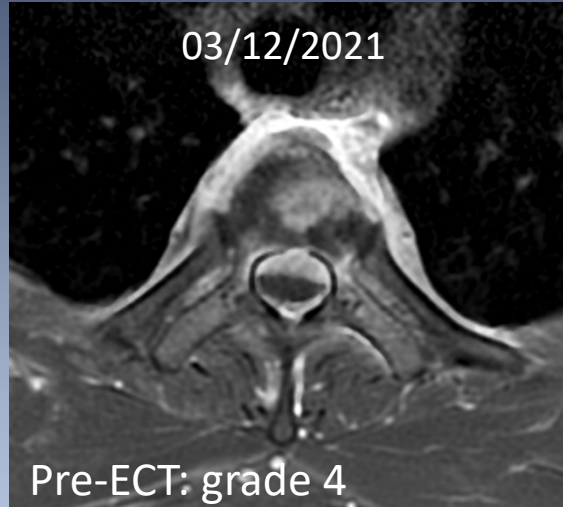08-09-2021
H

18-10-2021
HL

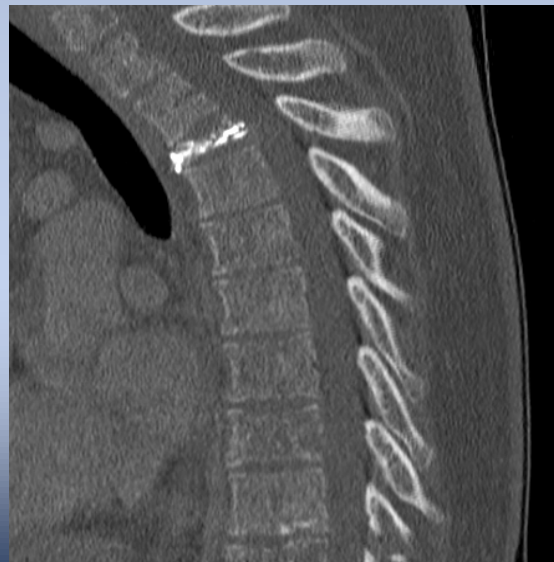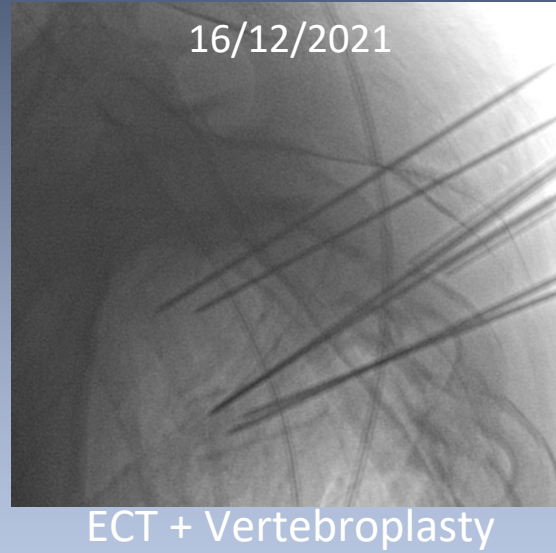
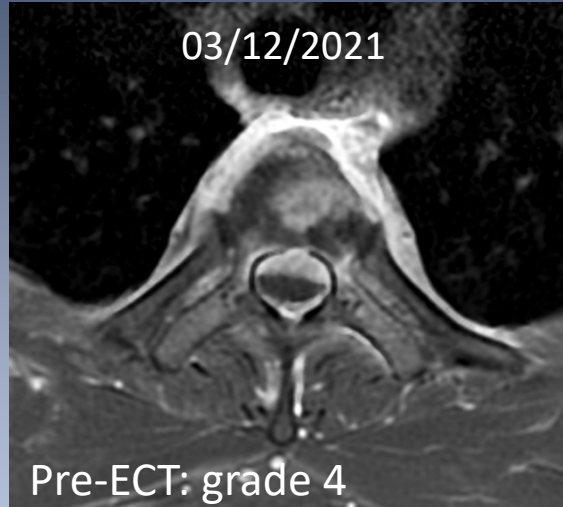13-12-2021
HR



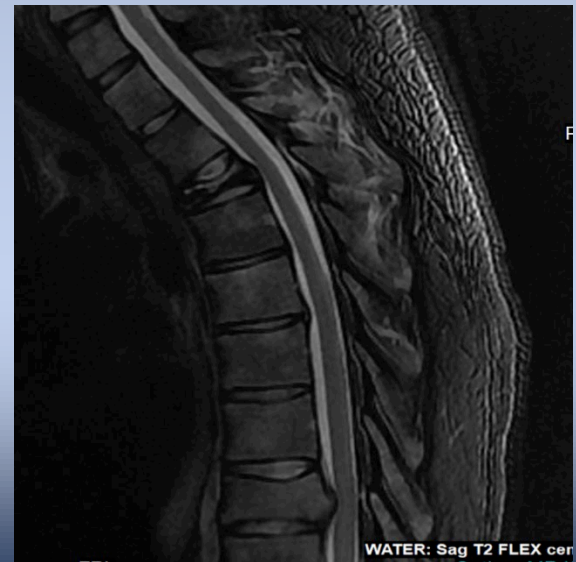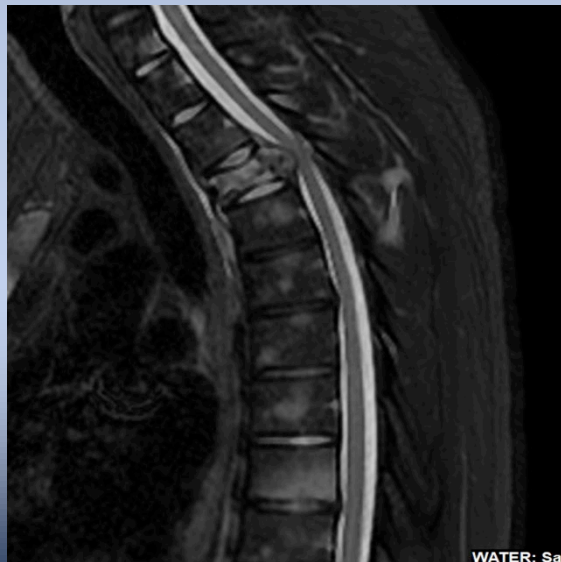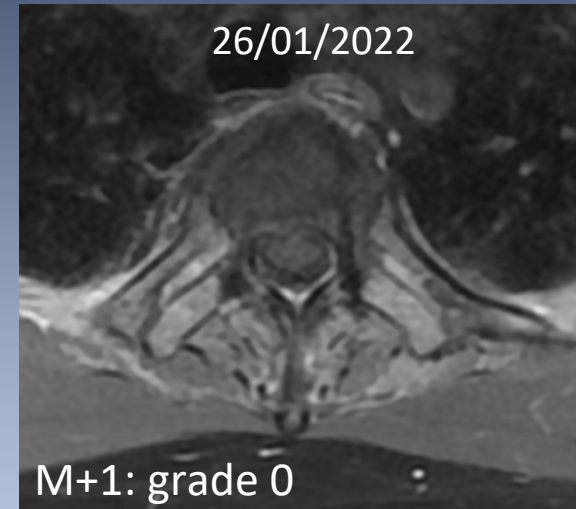
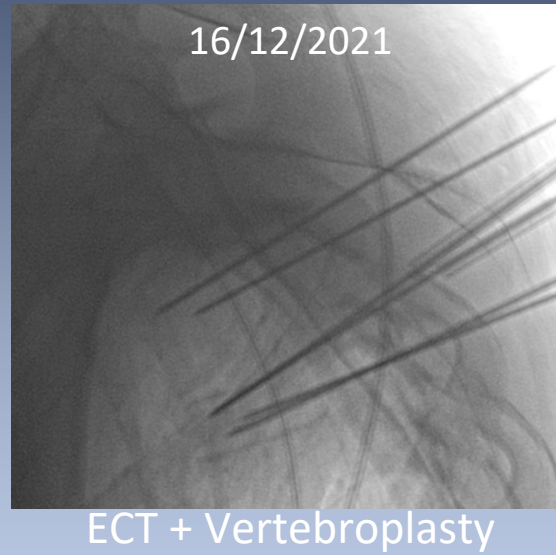
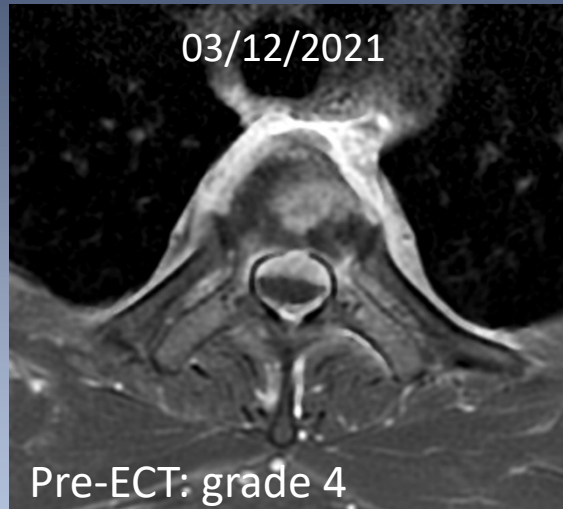25 yo, Rhabdomyosarcoma
T3 Progression despites cEBCT



25 yo, Rhabdomyosarcoma
T3 Progression despite cEBCT

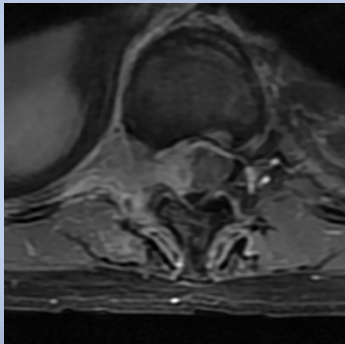
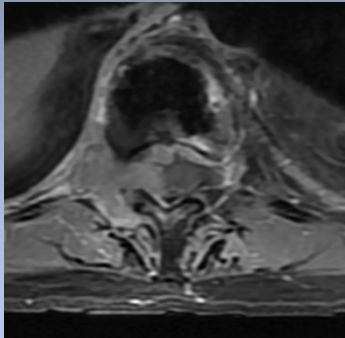
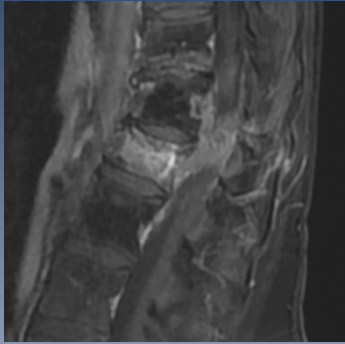


25 yo, Rhabdomyosarcoma
T3 Progression despites cEBCT

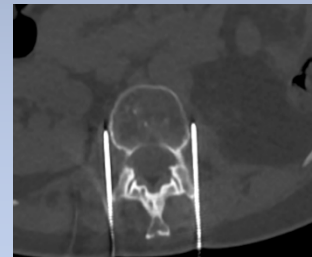
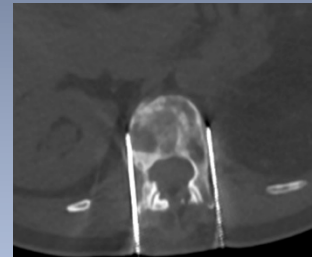
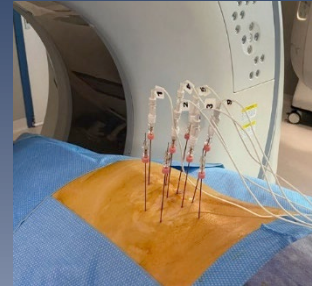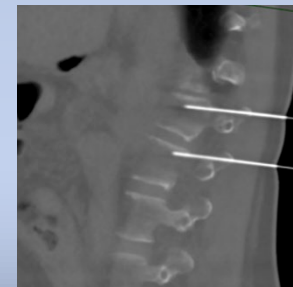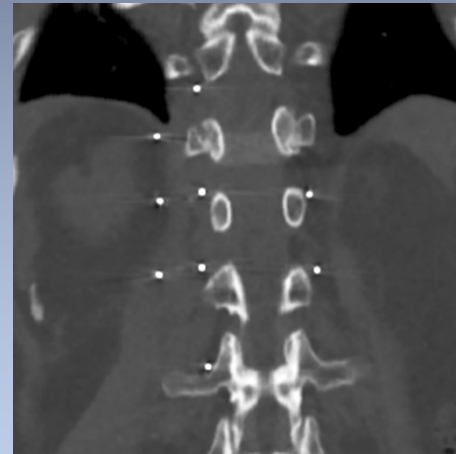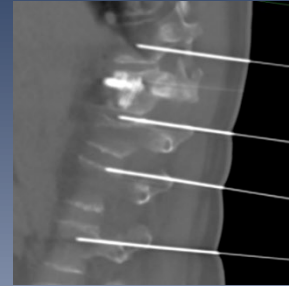
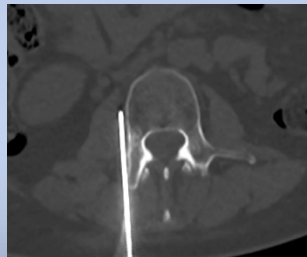
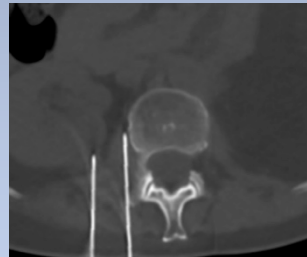
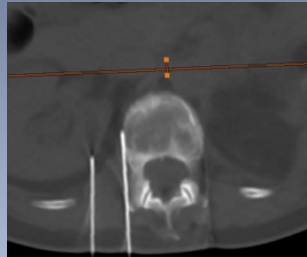
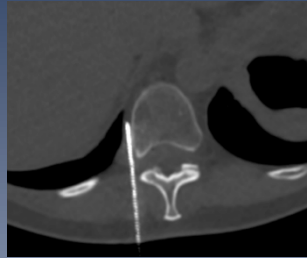


53 yo, Corticoadrenaloma

T12 progression despite SBRT, RFA and cement

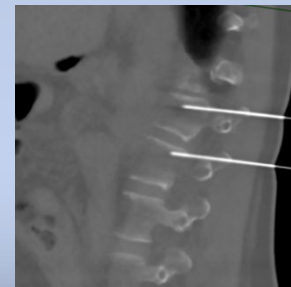
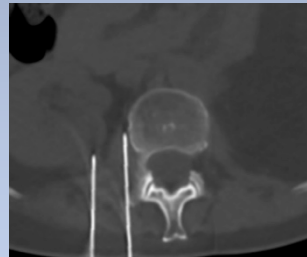
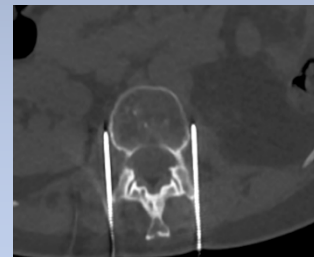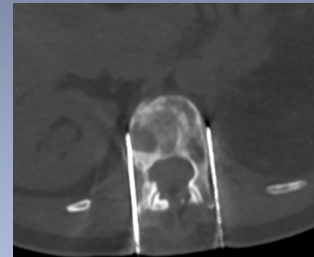
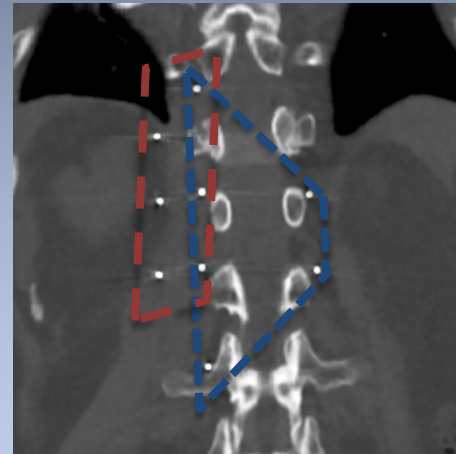
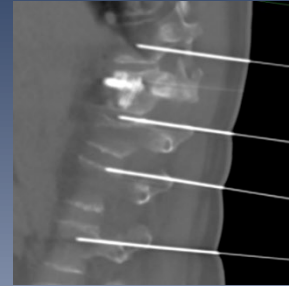
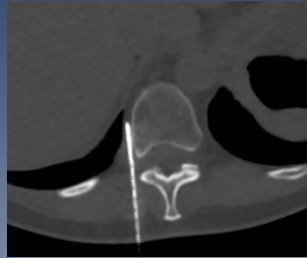

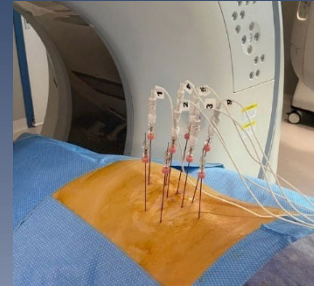

Pre-ECT: grade 4



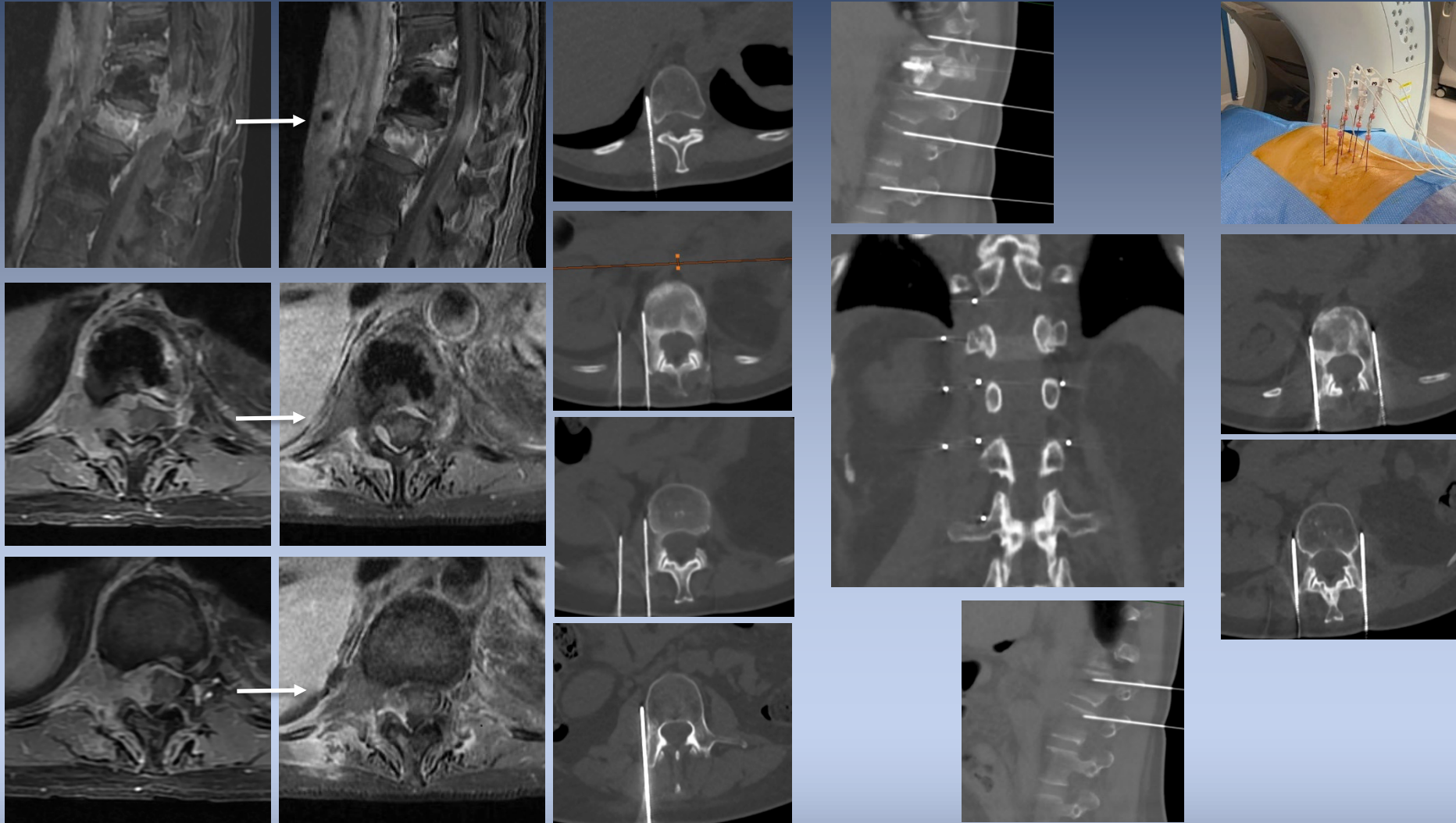
53 yo, Corticoadrenaloma

T12 progression despite SBRT, RFA and cement



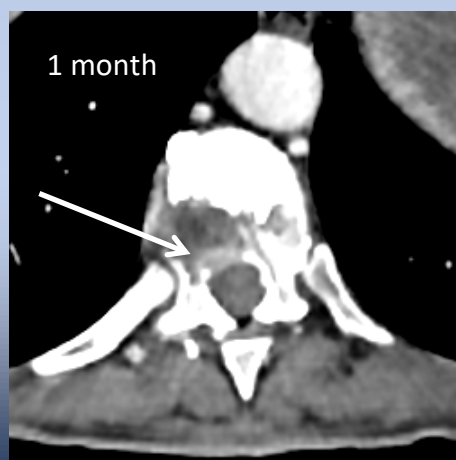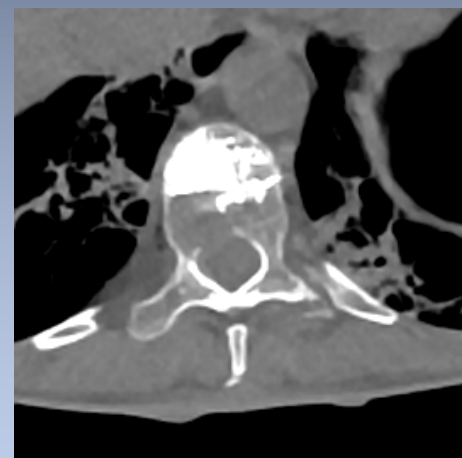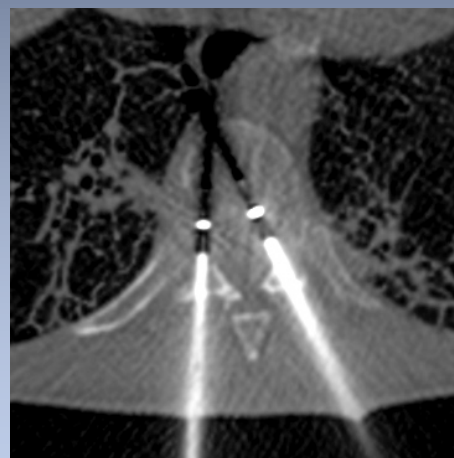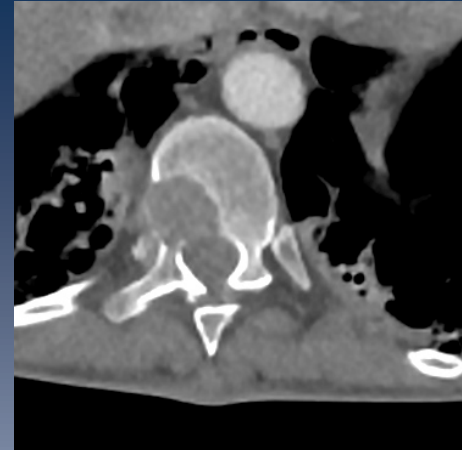
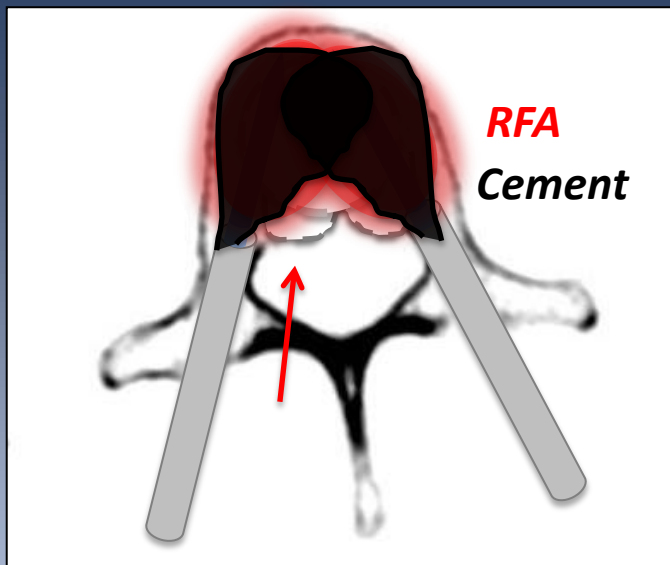
53 yo, Corticoadrenaloma

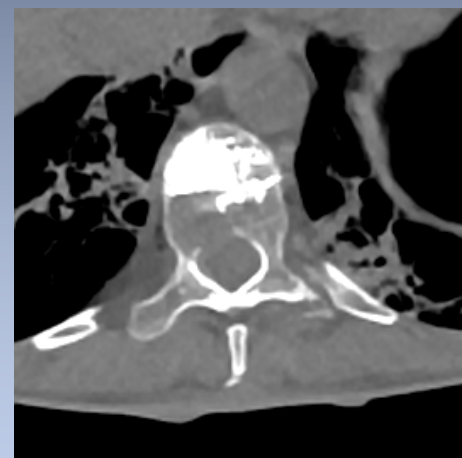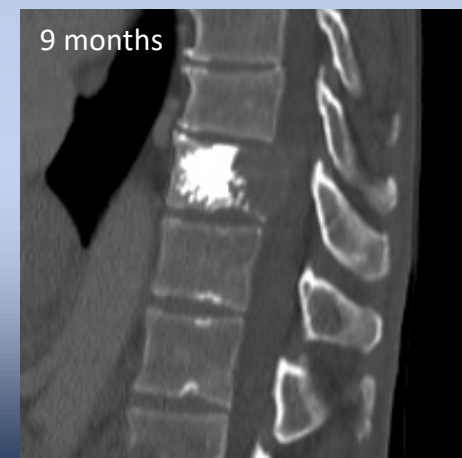
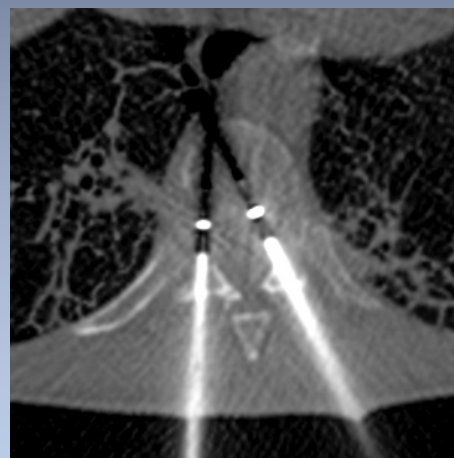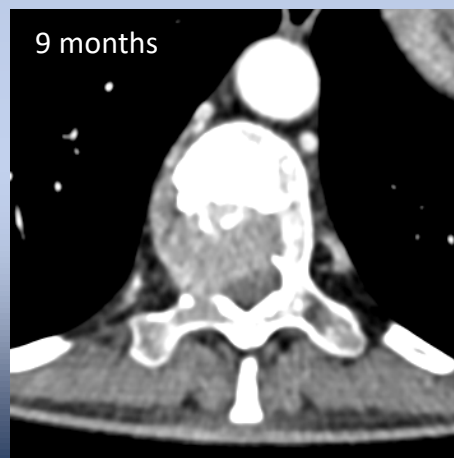
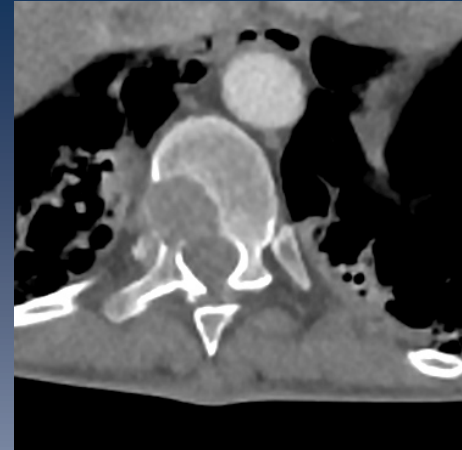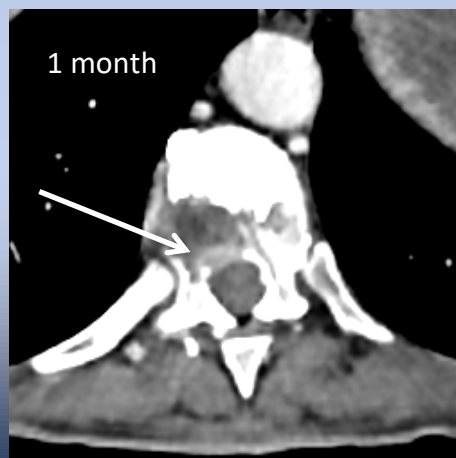
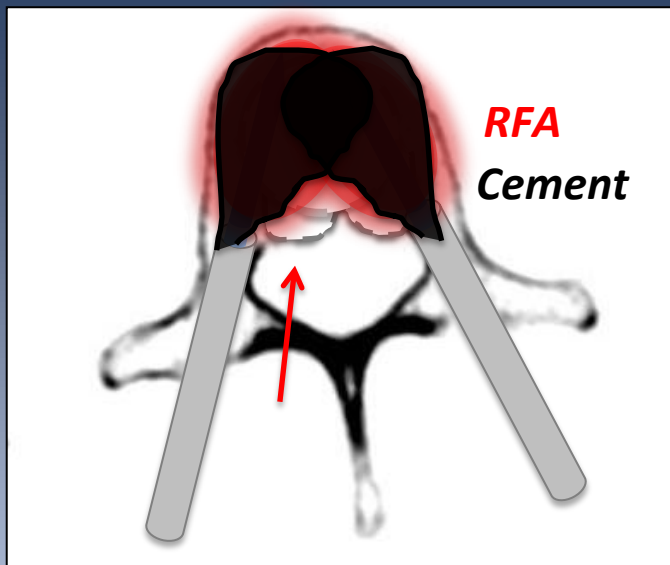
T12 progression despite SBRT, RFA and cement

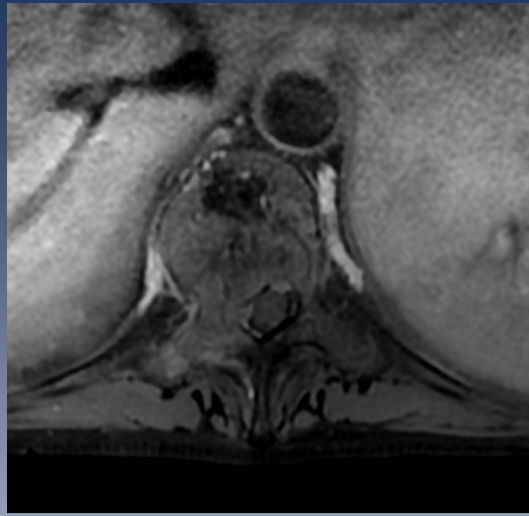
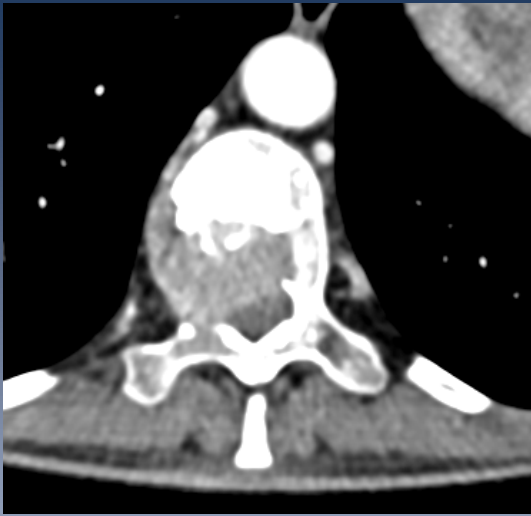


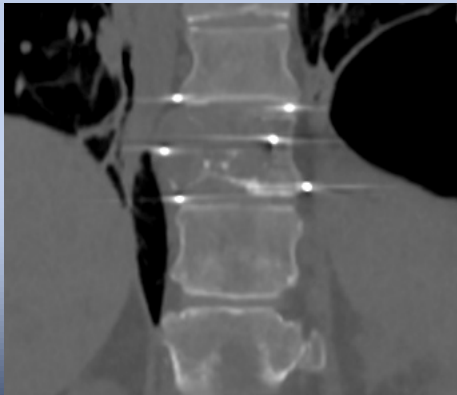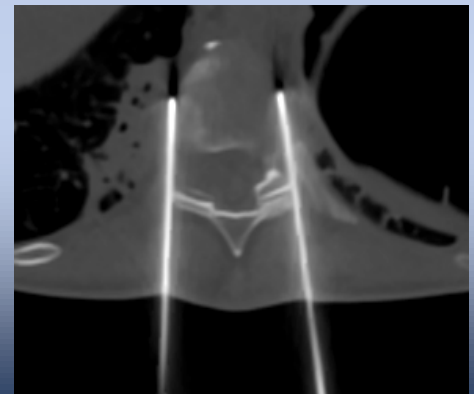
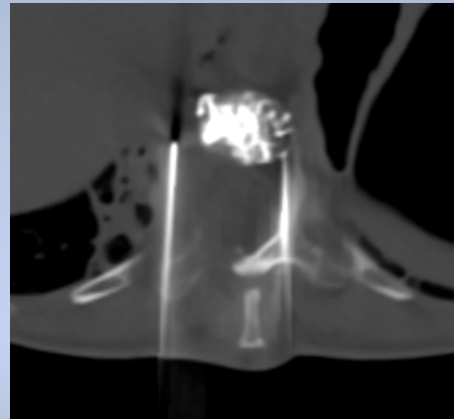
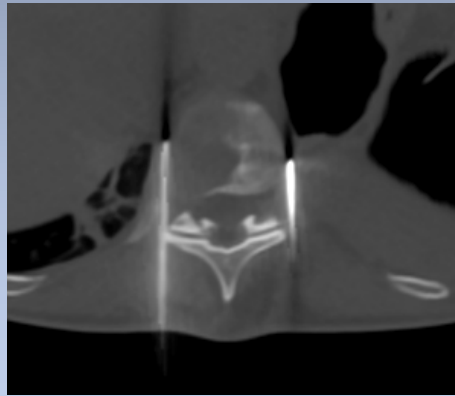
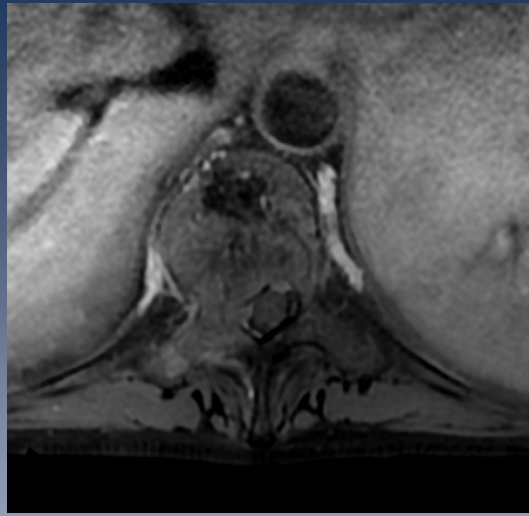
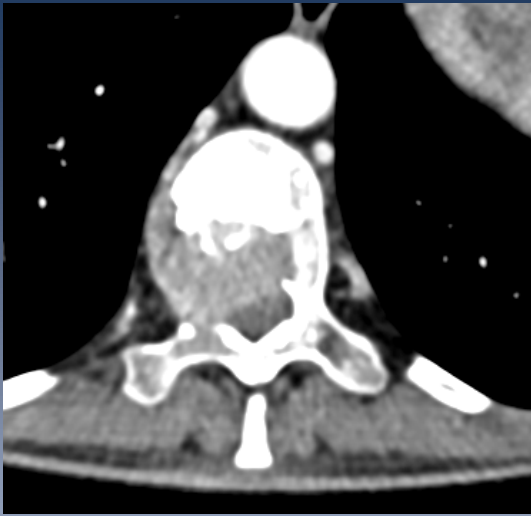
Pre-ECT: grade 4

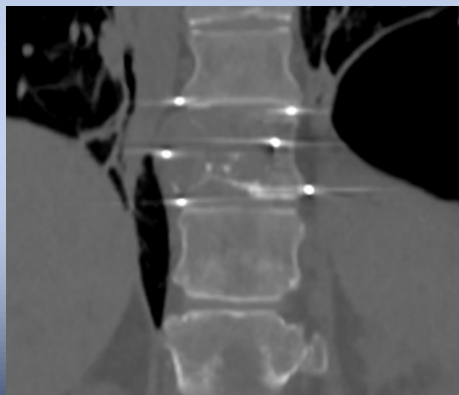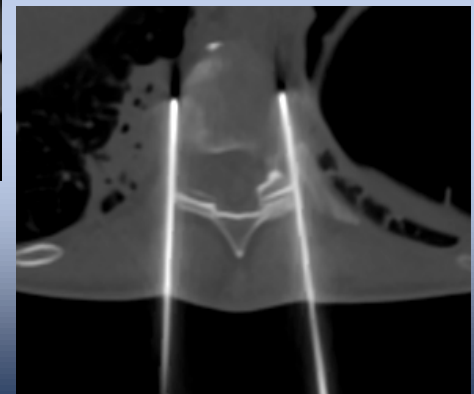
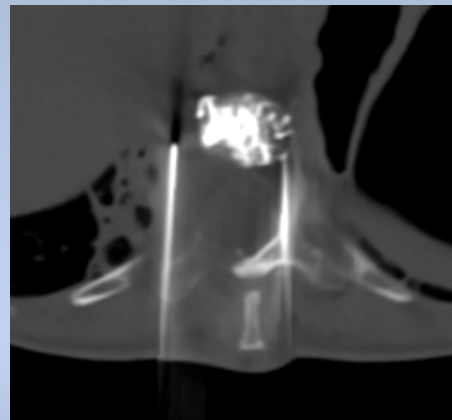
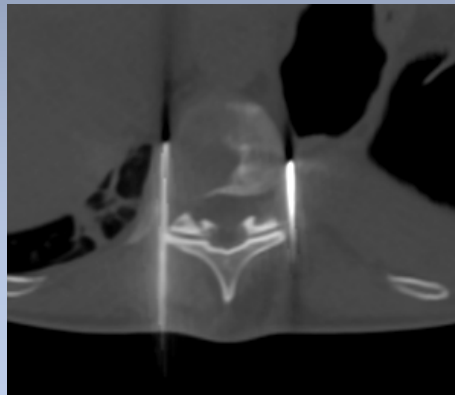
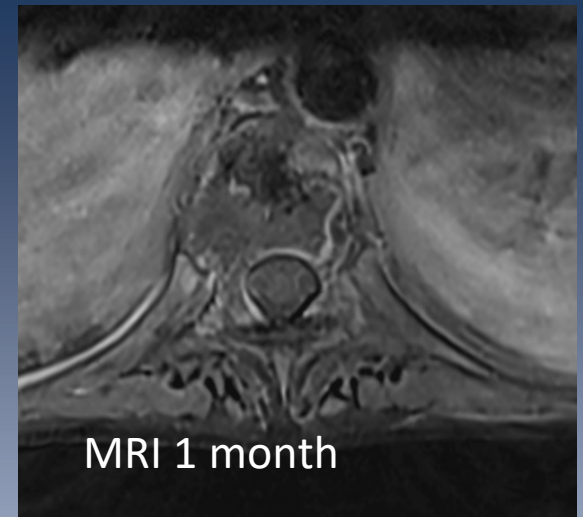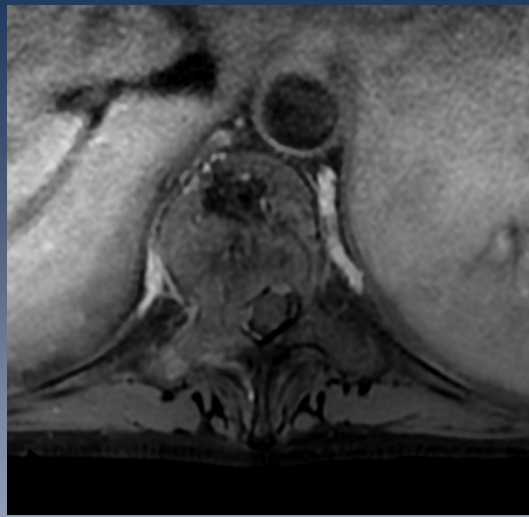
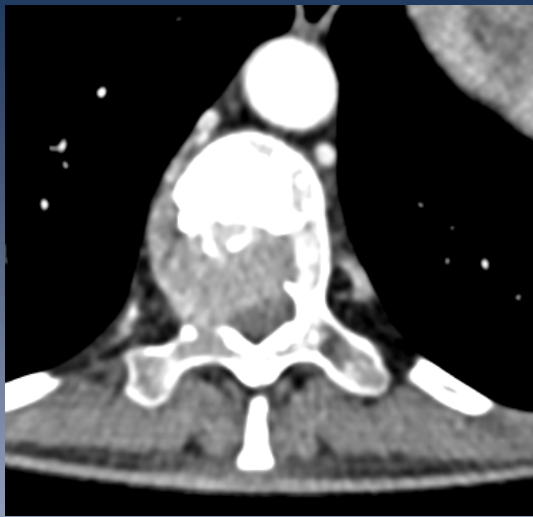M+1: grade 2

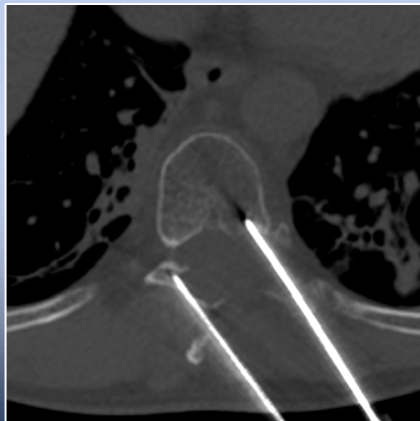
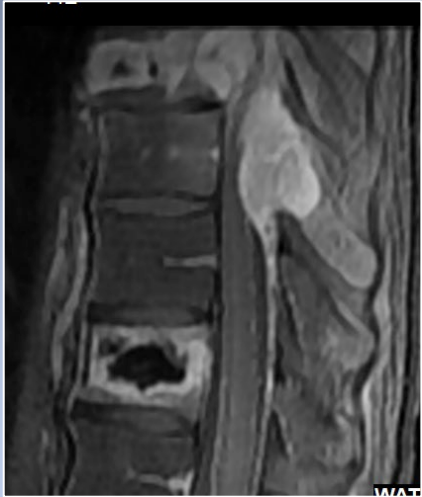
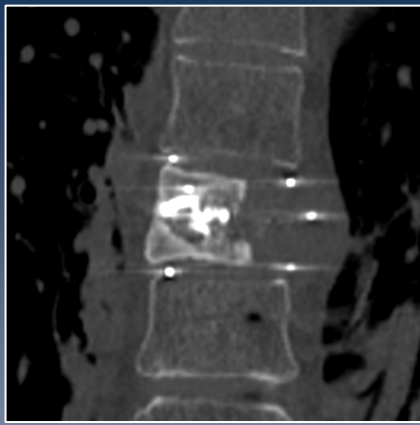
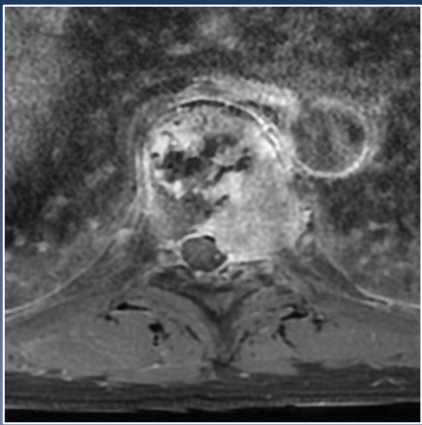




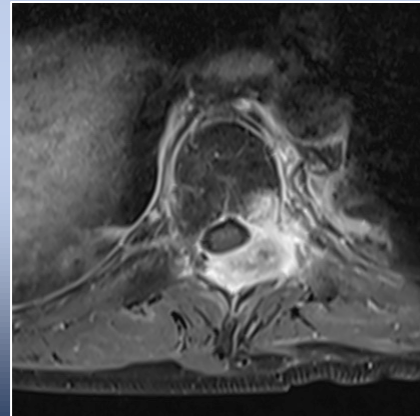
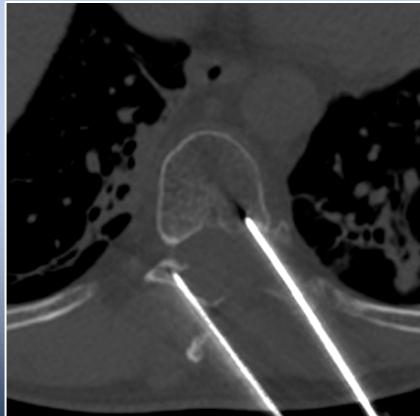
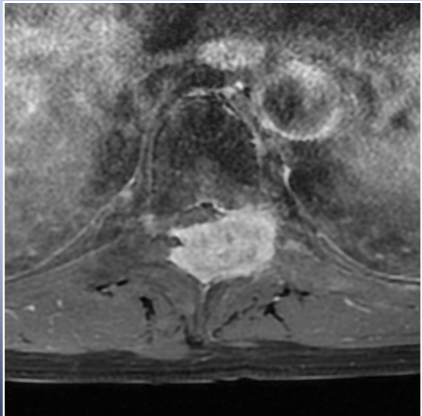
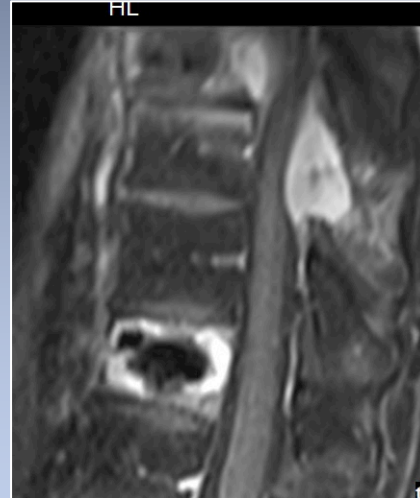
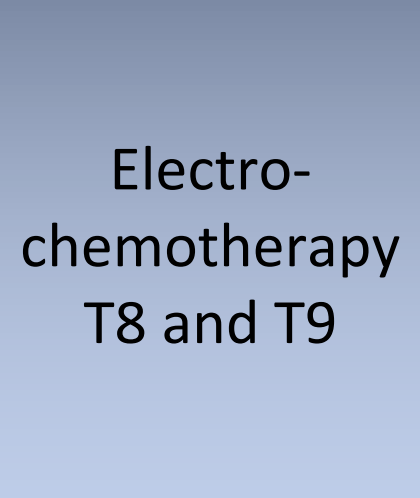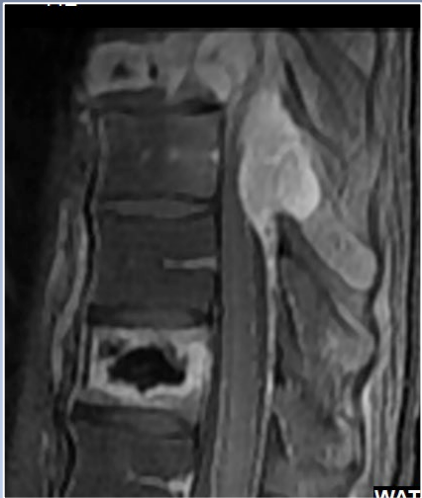
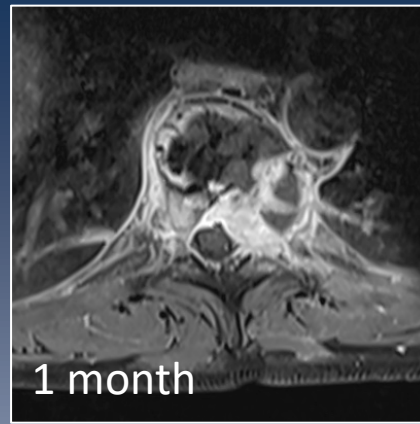
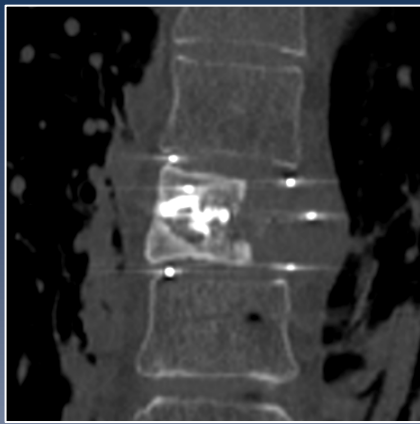
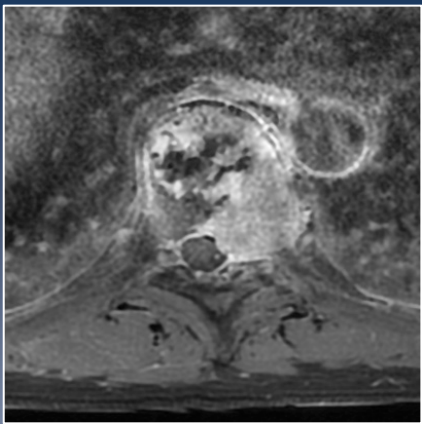




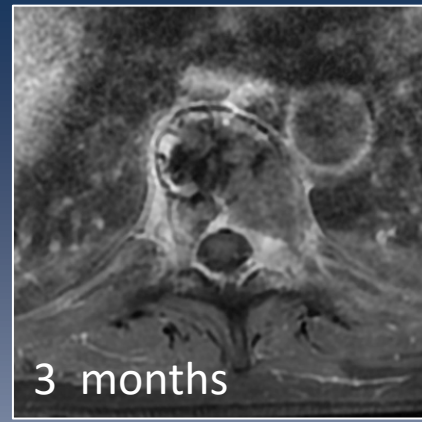
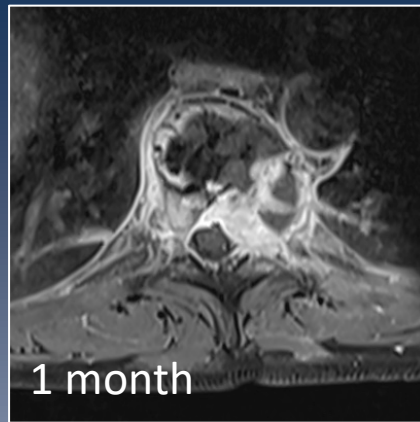
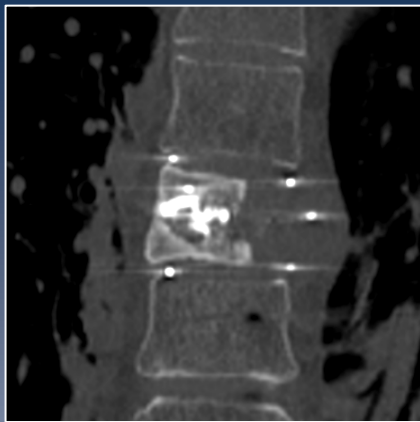
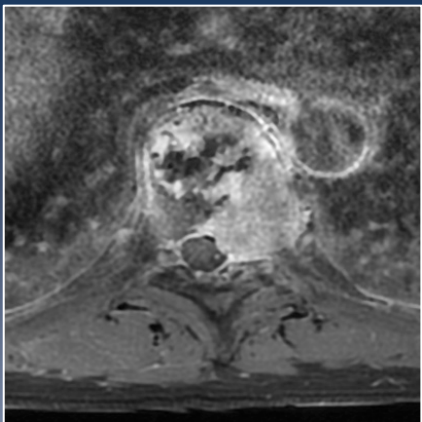




Electro-
chemotherapy
T8 and T9

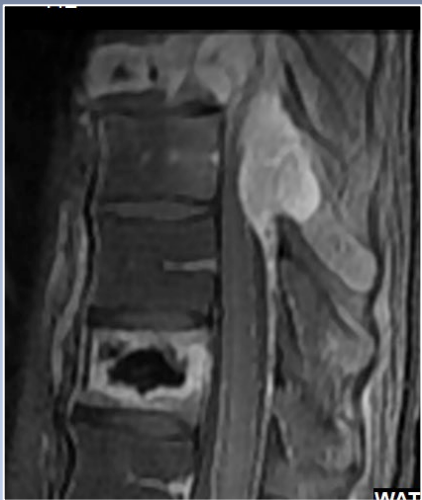


Electro-
chemotherapy
T8 and T9

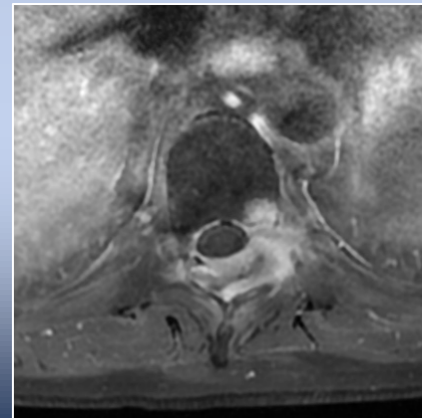
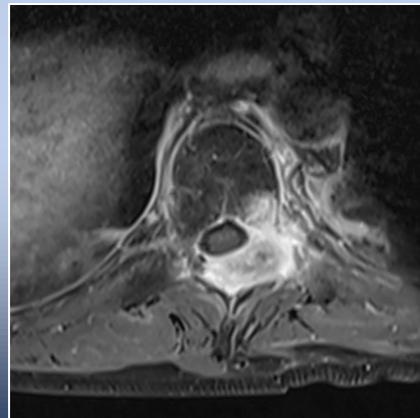
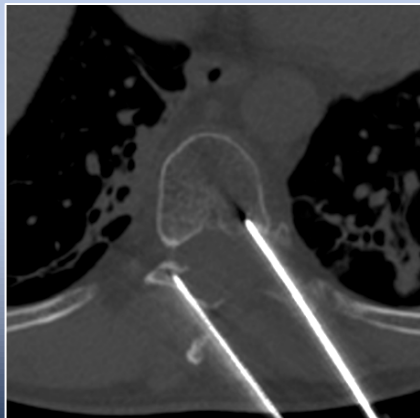
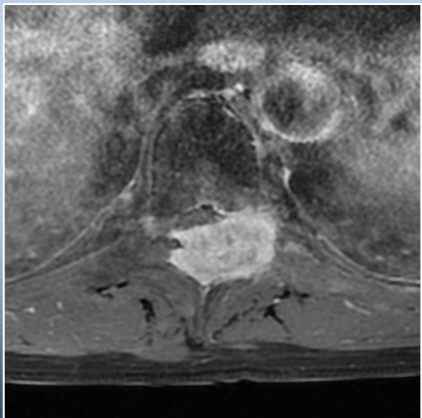
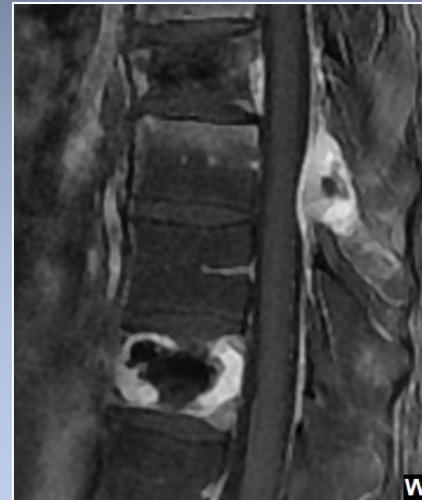
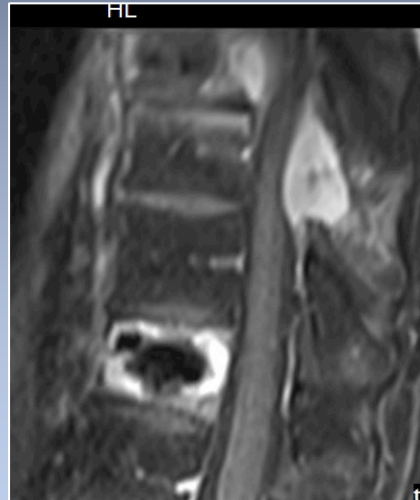


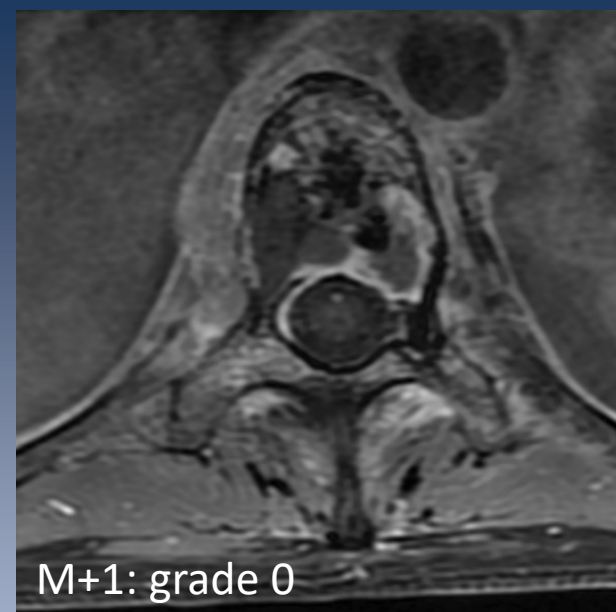
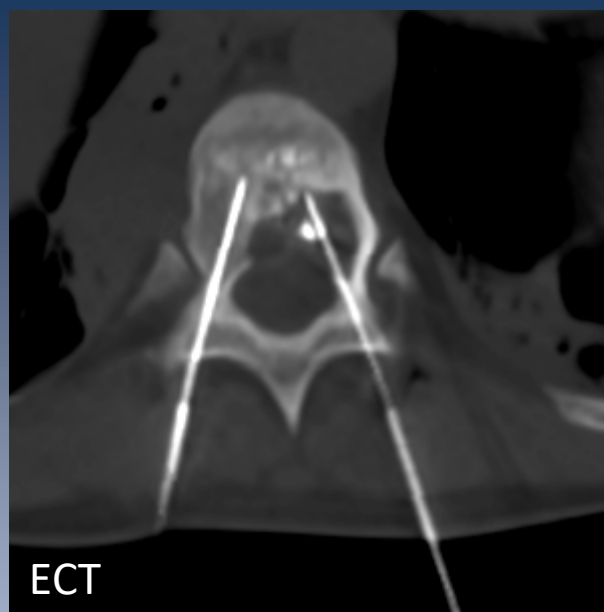
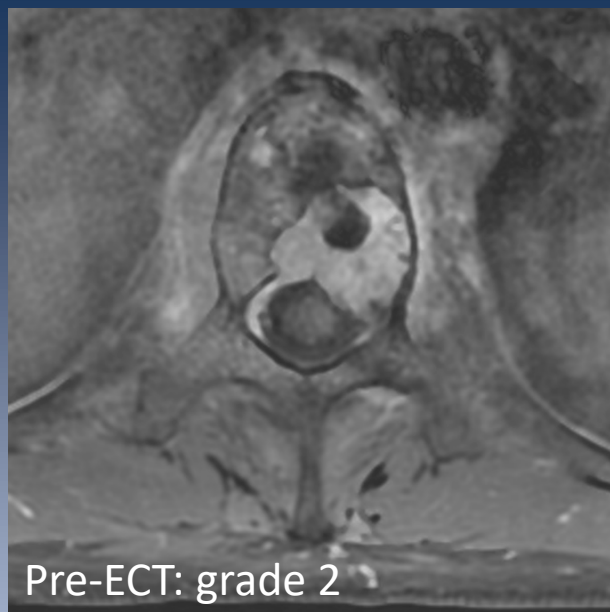
1 month

3 months



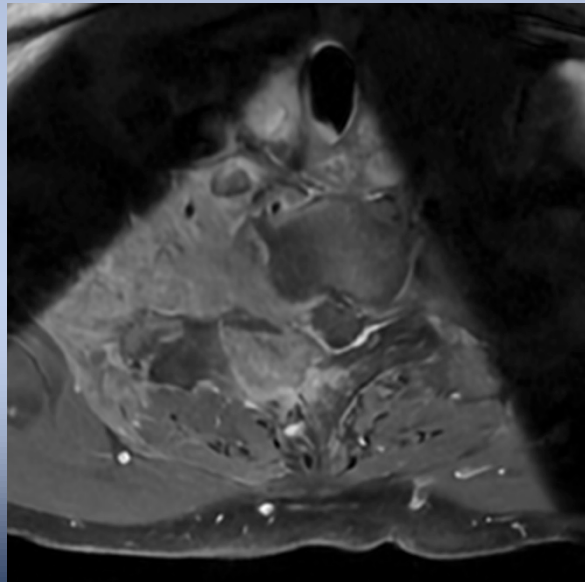
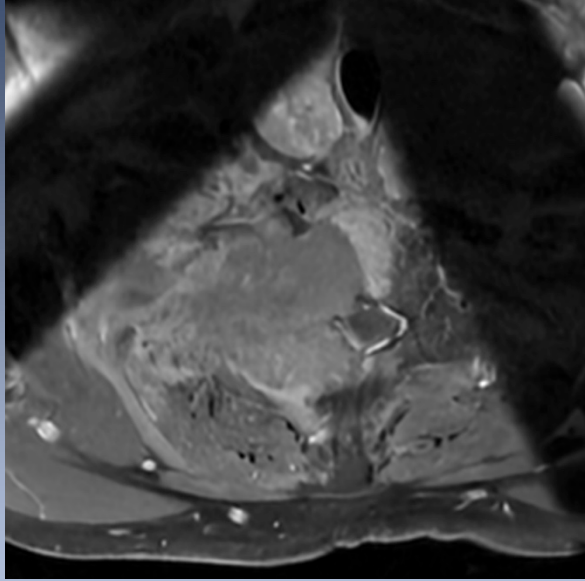
Electro-
chemotherapy
T8 and T9

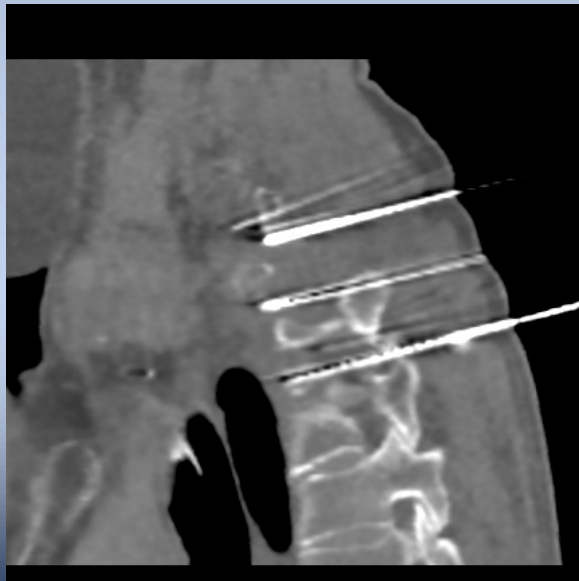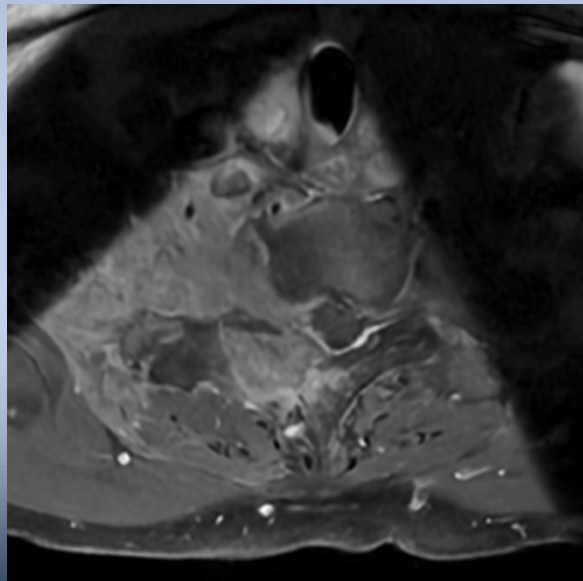
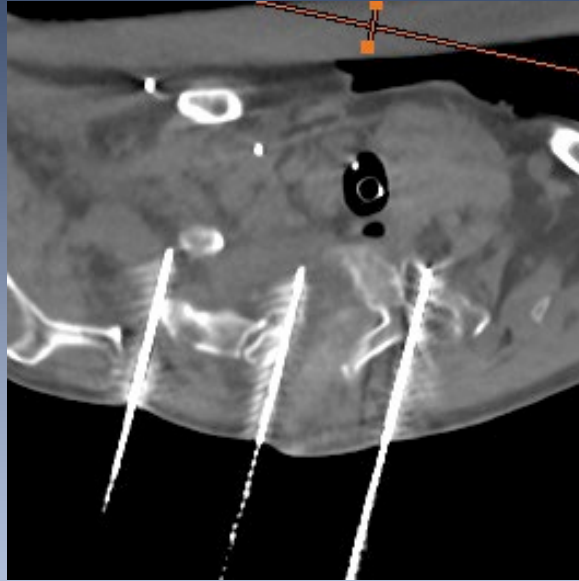
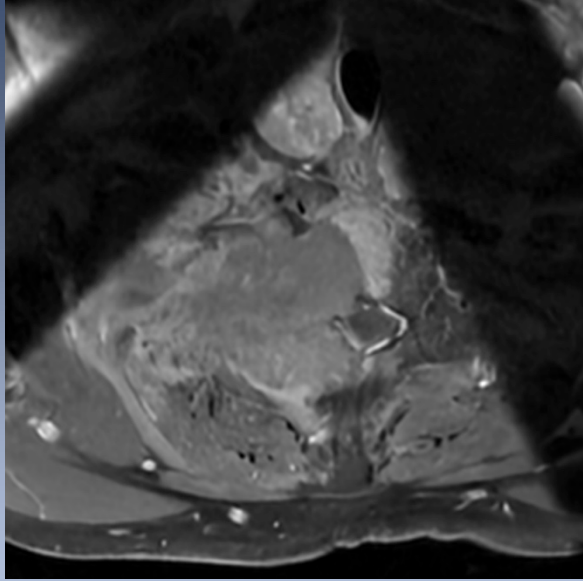


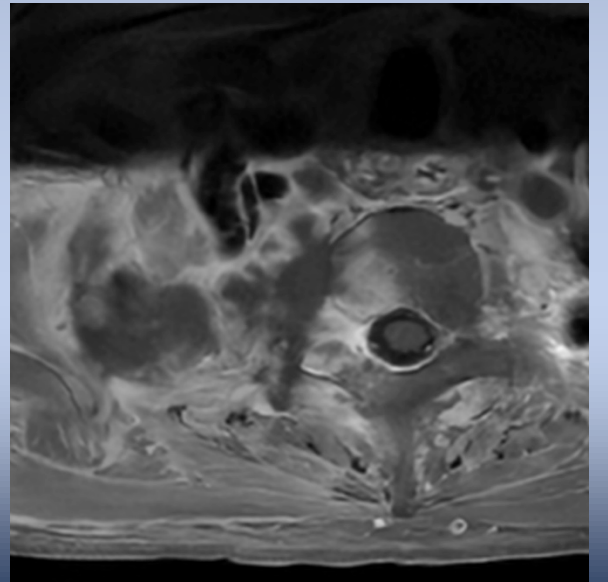
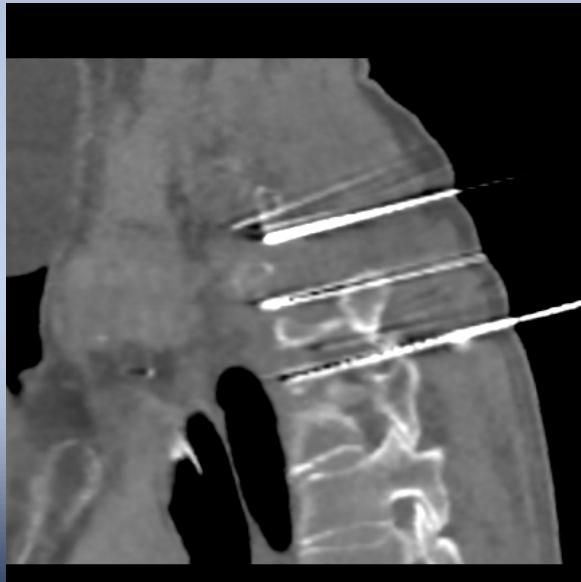
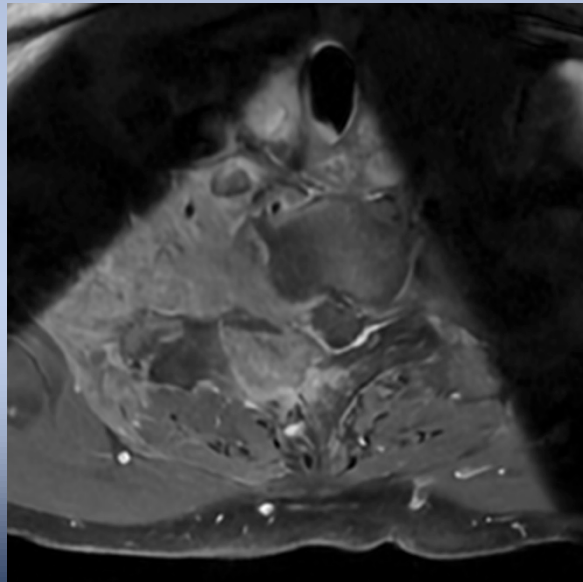
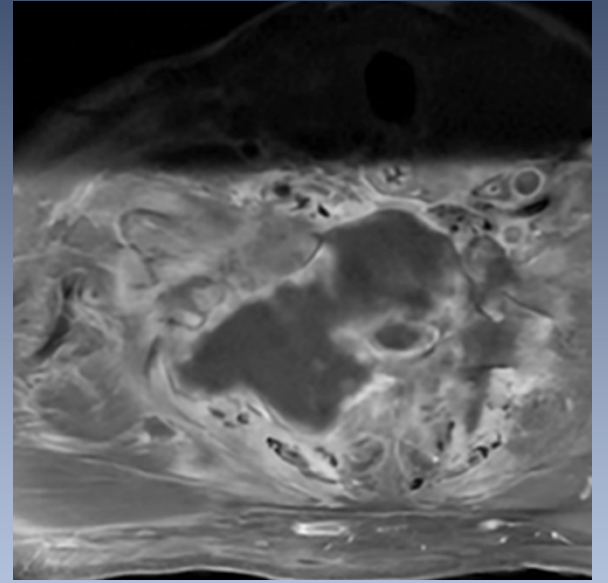
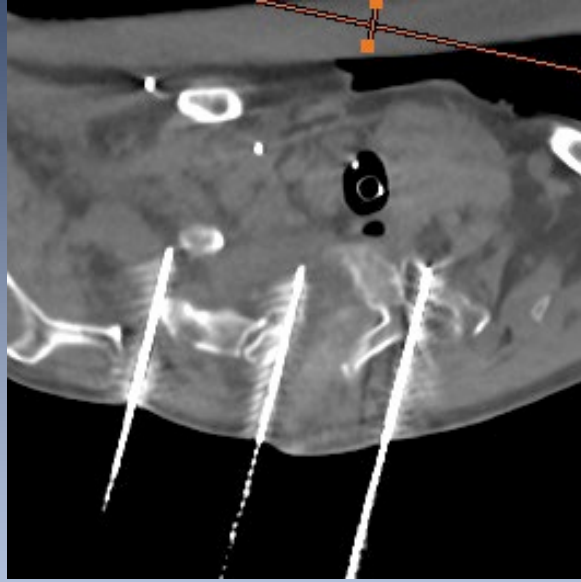
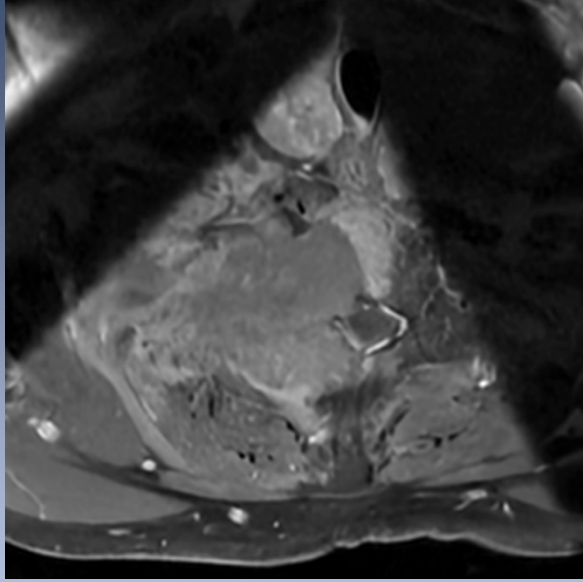


n= 40 patients (Feb. 2020 – Septembre 2022),

- VM with epidural extension between C5 and L1
- 1 level (n=21), 2 levels (n=9), 3 levels (n=5), 4 levels (n=3) and 5 levels (n=2)
- 9 with limited epidural involvement (grade 2) and with extended epidural involvement (grades 3, 4 and 5)

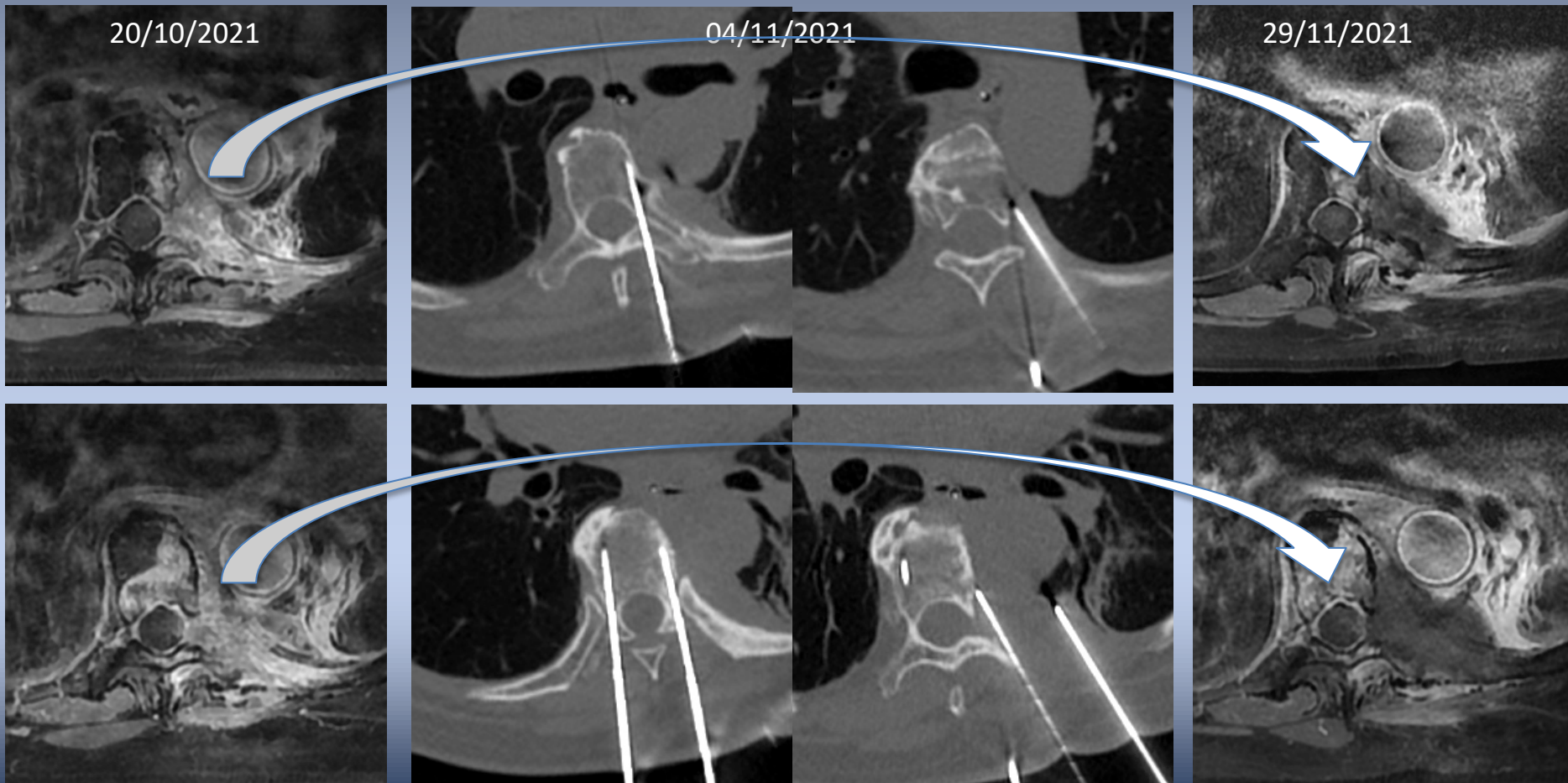






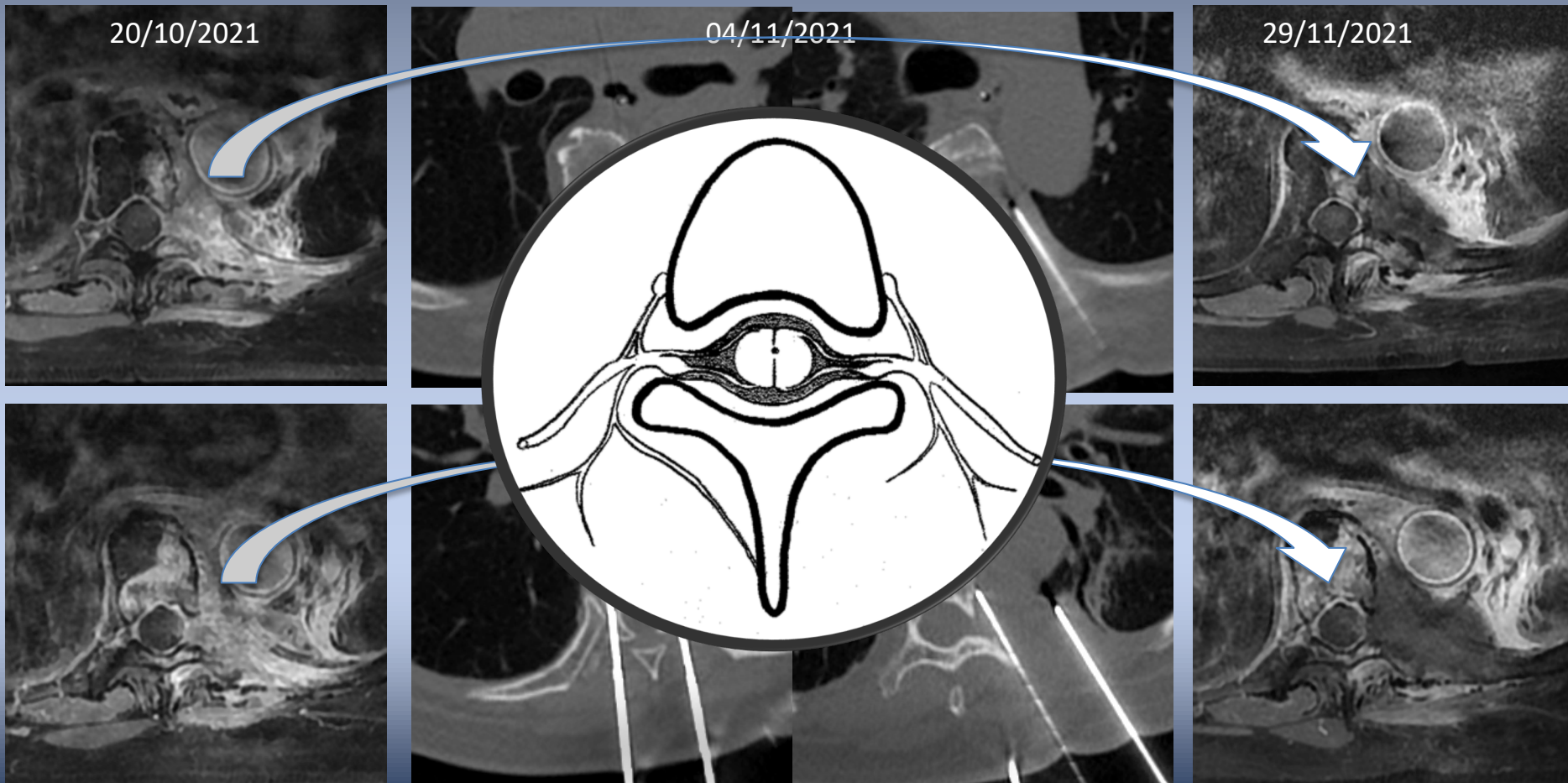
Complications

- Acute worsening of pain after a few days (25%) and prolong radicular hypoesthesia (10%) probably secondary to acute ECT-induced inflammation of the nerve roots.



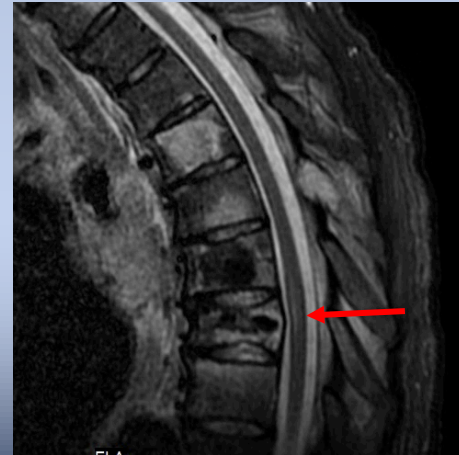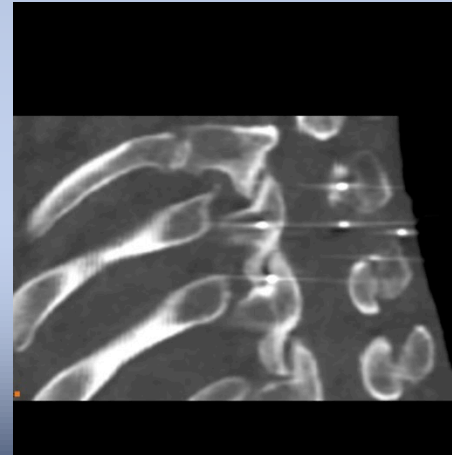
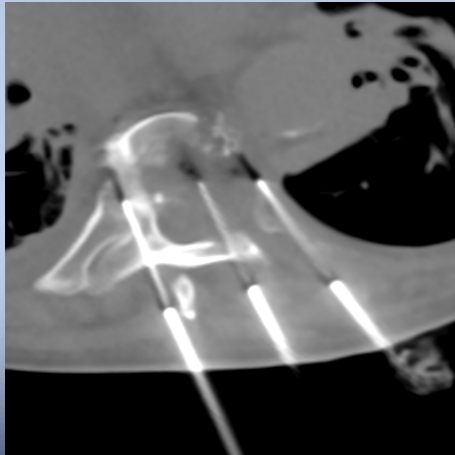
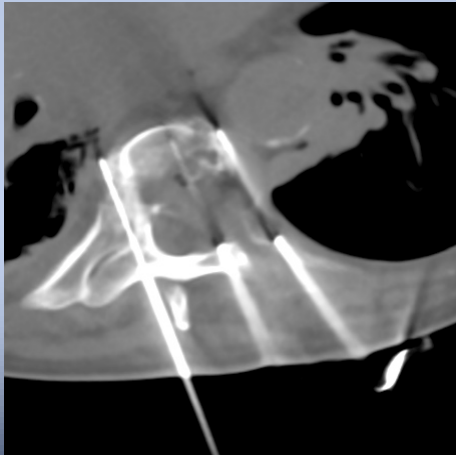
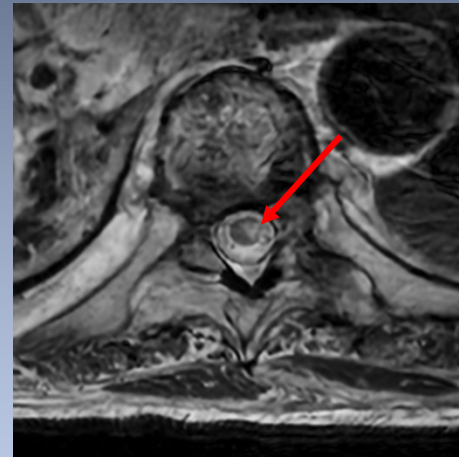
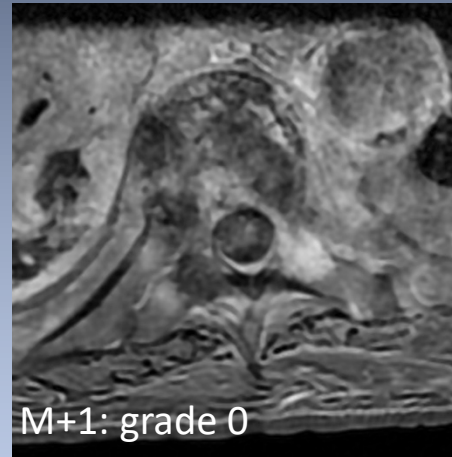
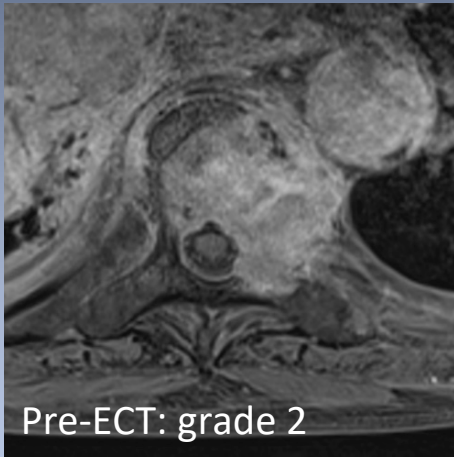
Complications

- Acute worsening of pain after a few days (30%) and radicular hypoesthesia (15%), mostly transient and probably secondary to acute ECT-induced inflammation of the nerve roots.



Complications

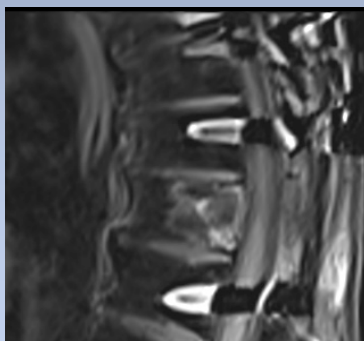
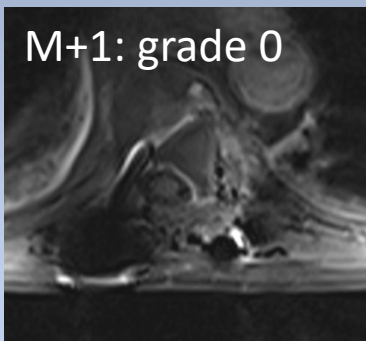
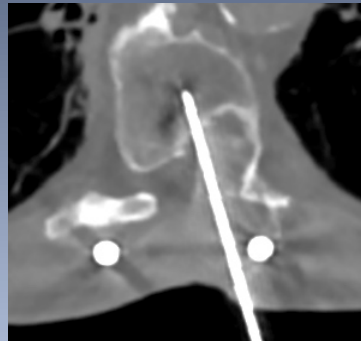
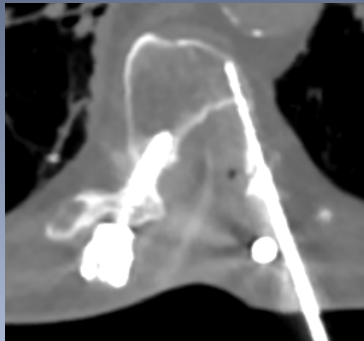
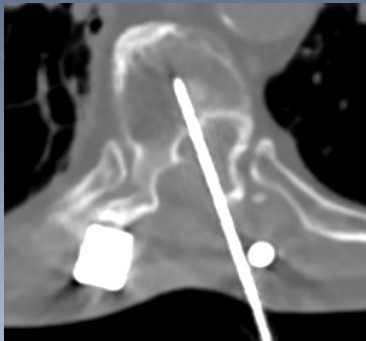
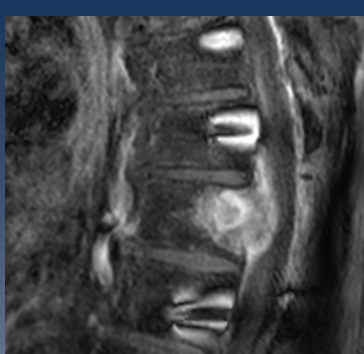
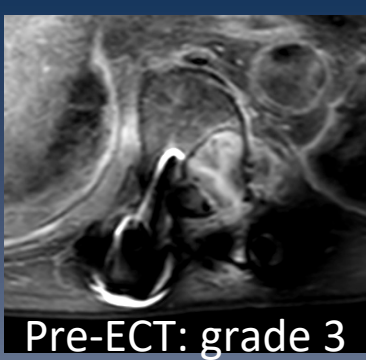
- 3 severe complications (7.5%) related to spinal cord damage:
Brown Sequard sd. (delayed at 2 weeks, persists at 3 months)



Follow-up?

At 1 month:

VAS: $6.1_{\pm 3.0}$ to $1.9_{\pm 2.3}$



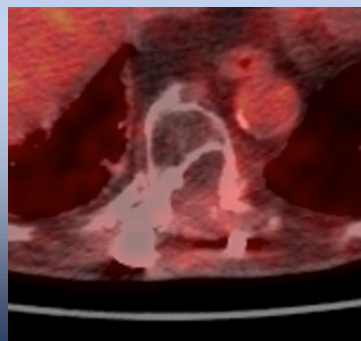
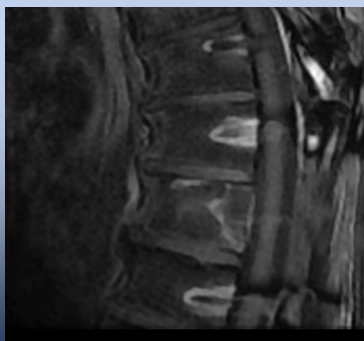
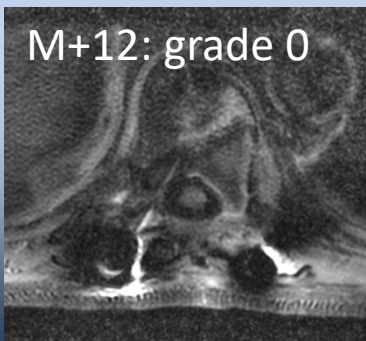
Epidural response at 1 month MRI (n=35) :

46% complete response (grade 0)

31% partial response (-1 point on Epidural scale)

23% Stable

0% progression



Long term follow-up?

Electro-CHEMOTHERAPIE

- New option for mets with epidural extention / compressing nerves
- Preliminary results are very promissing in term of short-term tumour control
- Long term follow-up is needed
- Rate of local complication is high and better understanding of the electric field across the spinal canal is mandatory

